



# المحاضرة الخامسة : الجلد وملحقاته

## Integumentary System

**ZUHEIR ALSHEHABI**

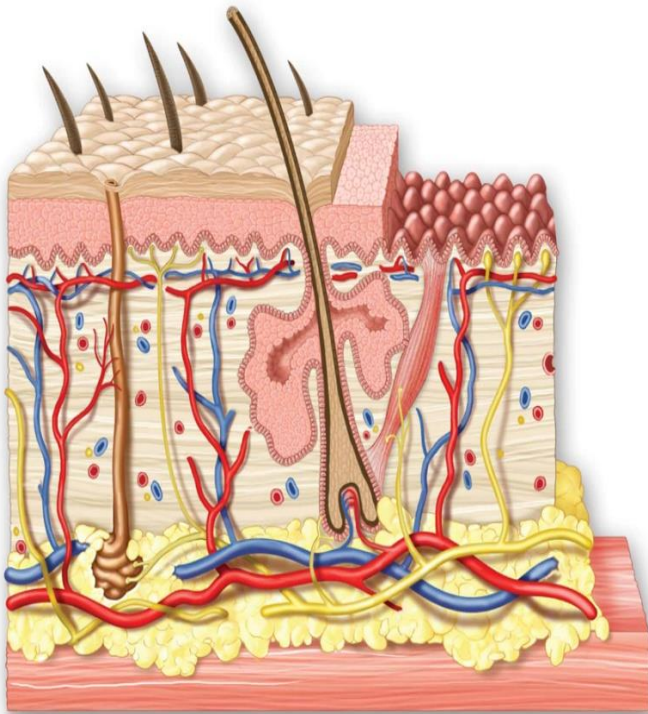
***MD, PHD, FASCP***

**2022**

<https://manara.edu.sy/>

# Medical Terminology

## A Living Language



## Integumentary System

### الجلد وملحقاته

# علم الأمراض Pathology

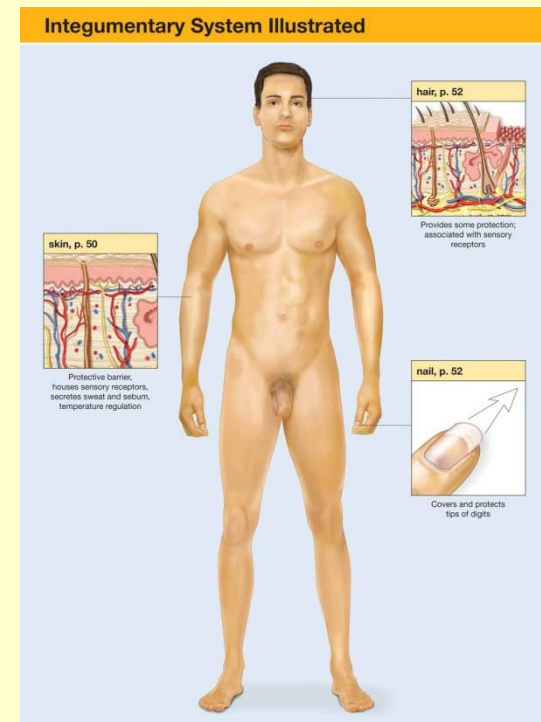
Study of Disease: (Pathology)

Pathos = Disease + Logy = Science



# Integumentary System at a Glance

- Organs of Integumentary System
  - Skin
  - Hair
  - Nails
  - Sebaceous glands
  - Sweat glands

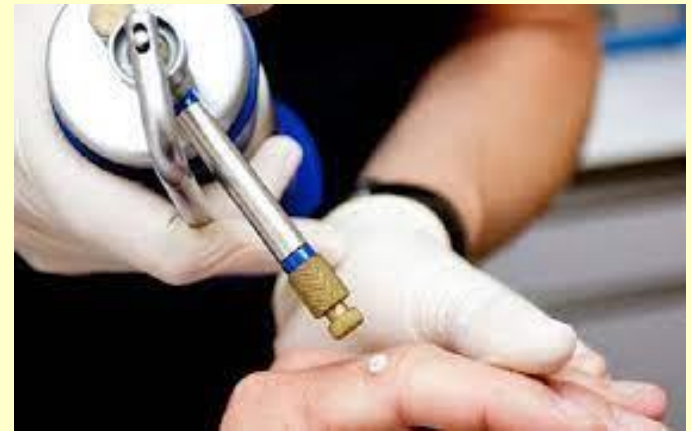

# Integumentary Combining Forms

## الأشكال المؤلفة

- albin/o أبيض white
- melan/o أسود black
- cry/o قري ، بارد cold
- cutane/o جلدي skin
- cyan/o ازرقاق blue
- dermat/o جلدي skin

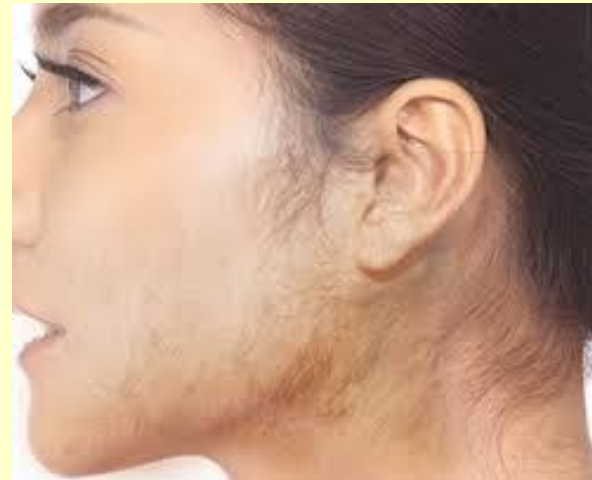العلاج بالتبريد Cryotherapy



# Integumentary Combining Forms

- lip/o شحمي fat
- myc/o فطر fungus
- trich/o شعر hair
- py/o قيح pus
- scler/o صلابة hard
- erythr/o أحمرار red
- hidr/o عرقي sweat
- kerat/o قرني hard, horny

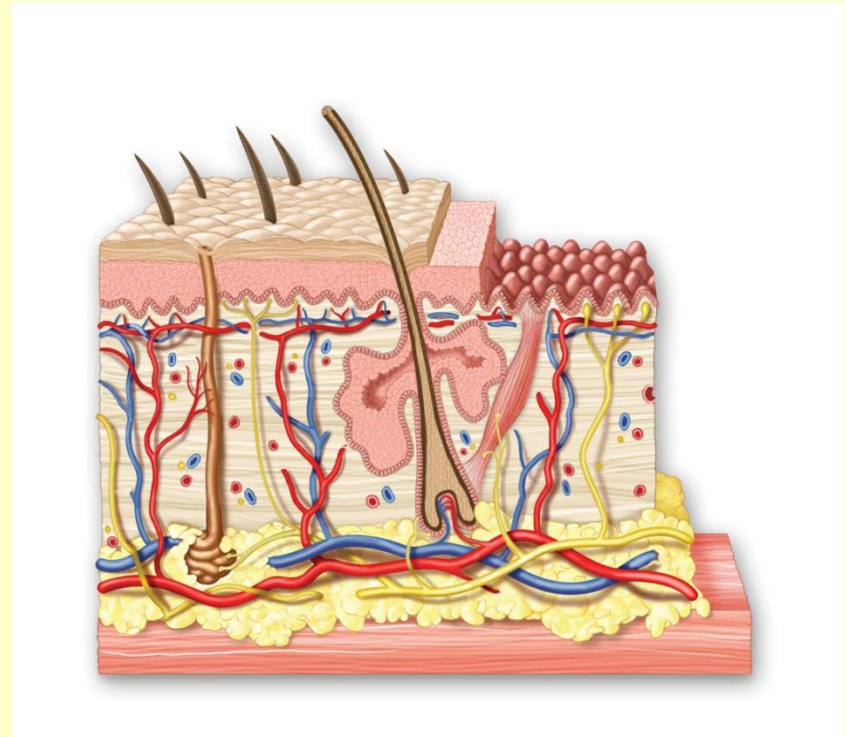
Hyper-tricho-sis



Hirsutism

# Anatomy تشریح

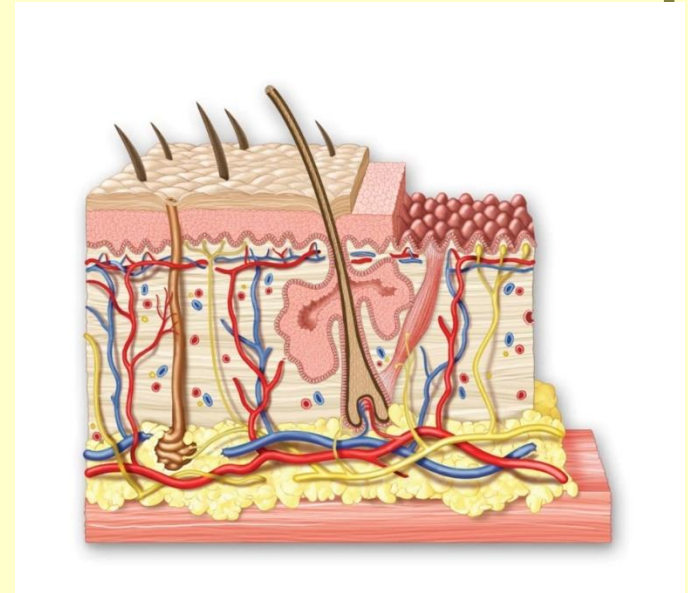
- Skin
- Accessory organs
  - **Sweat glands**
  - **Sebaceous glands**
  - **Hair**
  - **Nails**



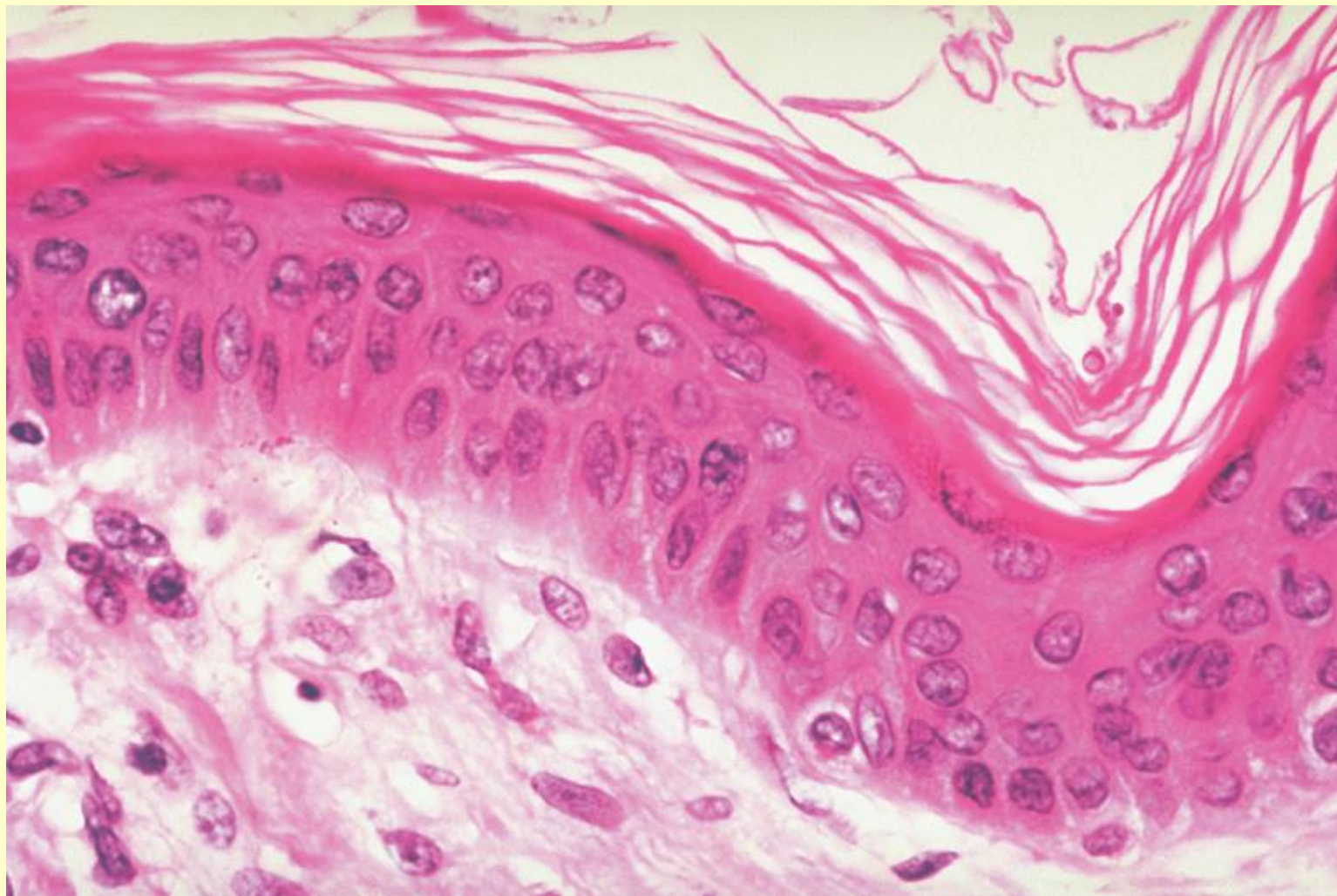


# The Skin

- Three layers
  - **Epidermis** – thin, outer membrane layer
  - **Dermis** – middle, fibrous connective tissue layer
  - **Subcutaneous layer** – innermost layer of fatty tissue







Photomicrograph of the epidermis layer of the skin.

# Word Building with cutane/o & dermat/o

sub— —ous	Subcutaneous تحت الجلد	pertaining to under skin
epi— —al	Epidermal بشروي	pertaining to upon skin
intra— —al	Intradermal داخل الأدمة	Peprtaining to within skin

# Word Building with dermat/o

–itis	Dermatitis التهاب الجلد	inflammation of skin
–logist	Dermatologist أخصائي جلدية	skin specialist
–osis	Dermatosis جلاد	abnormal skin condition

# Word Building with melan/o & necr/o

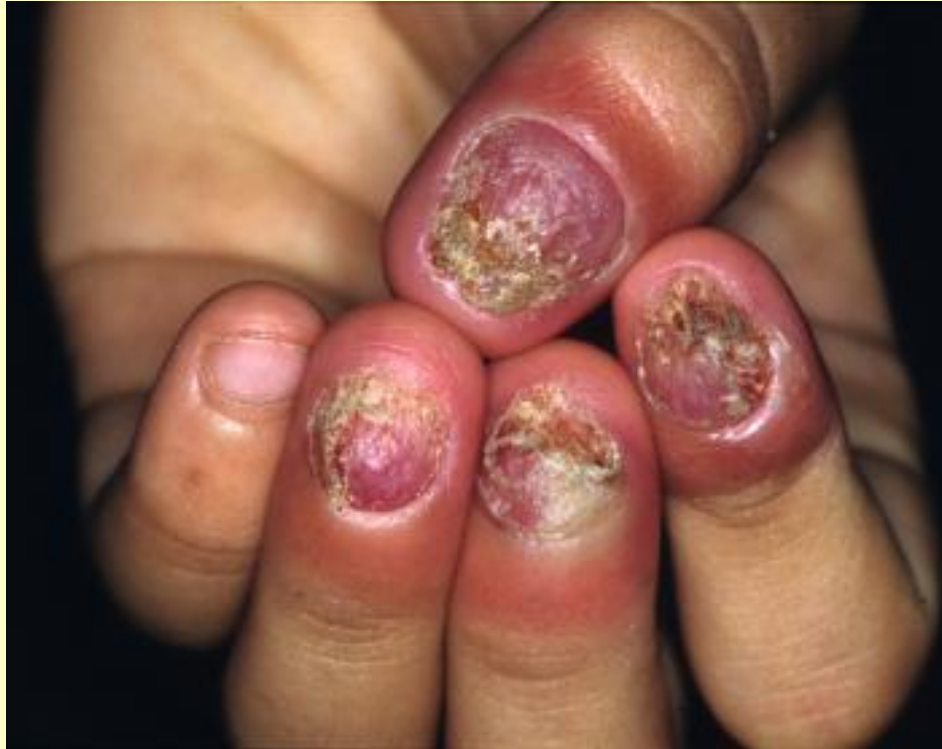–oma	Melanoma ورم قتاميني	black tumor
–cyte	Melanocyte خلية قتامينية	black cell

–osis	Necrosis نخر	abnormal condition of death
-------	-----------------	--------------------------------

# Word Building with: onych/o

myc/o –osis	Onychomycosis فطور الأظافر	abnormal condition of nail fungus
-------------	-------------------------------	--------------------------------------

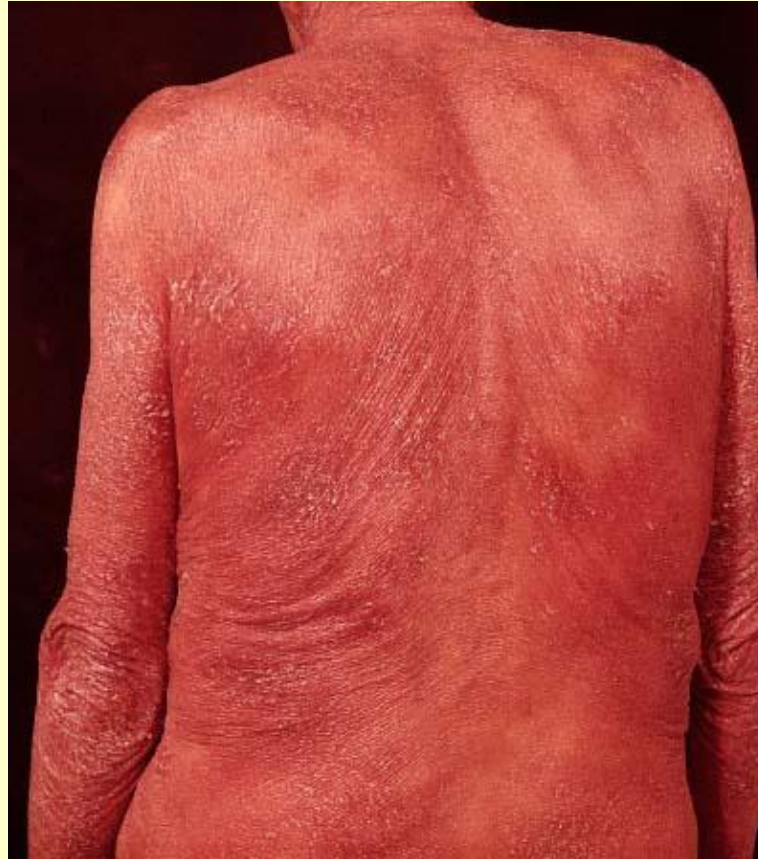

# Word Building with –derma

erythr/o	Erythroderma احمرية جلدية	red skin
leuk/o	Leukoderma ابيضاض	white skin
py/o	Pyoderma تقيح	pus skin
scler/o	Scleroderma صلابة	hard skin

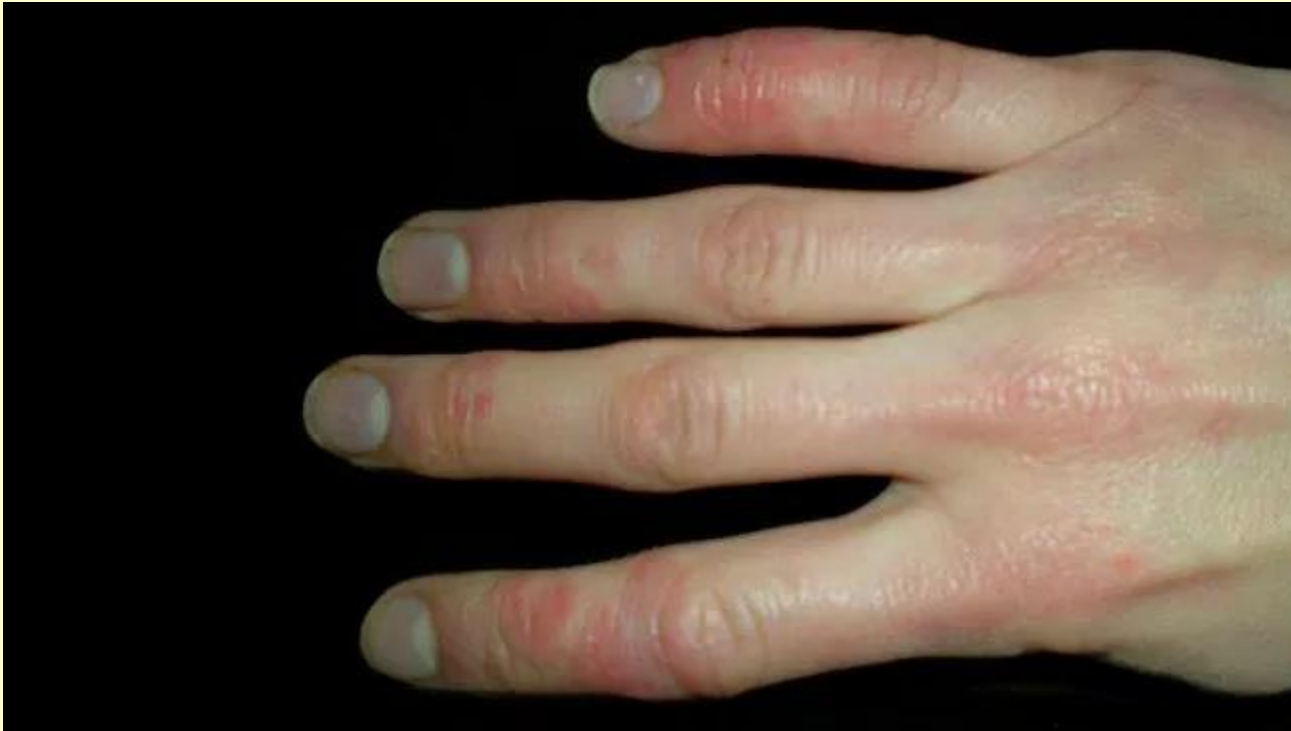

# أحمرية جلدية Erythroderma





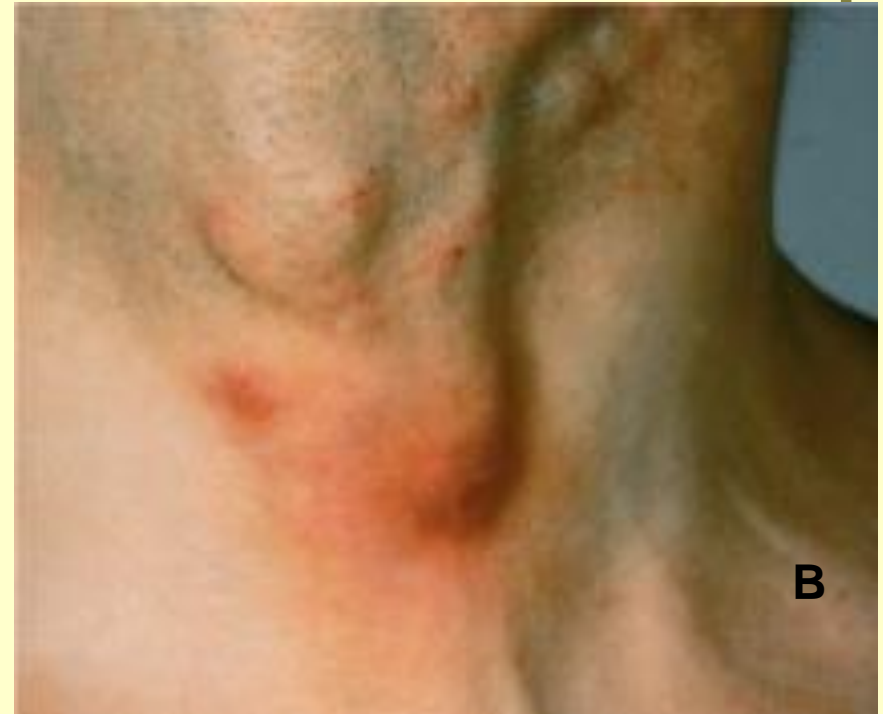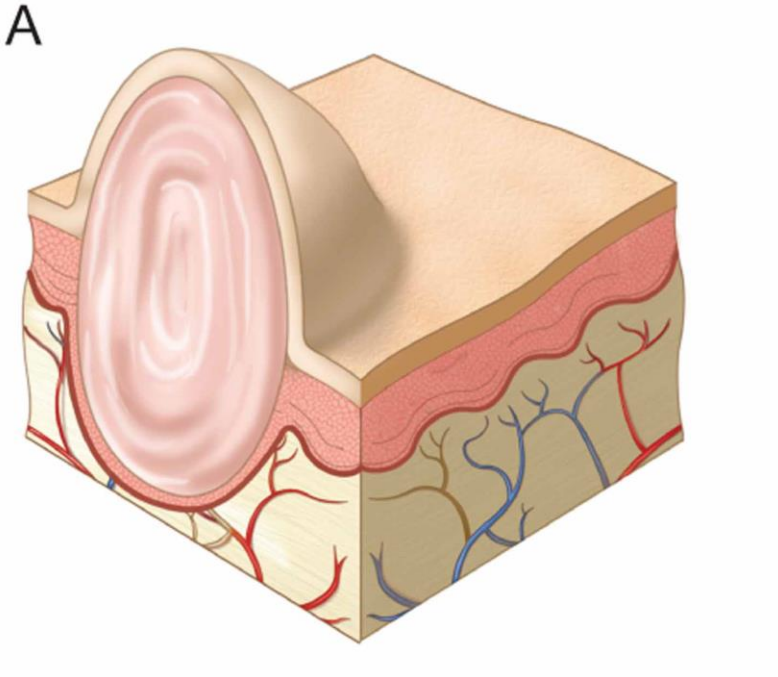
# Scleroderma صلابة الجلد



# Pathology – Surface Lesions

Cyst	كيسة	fluid-filled sac under skin
Fissure	شق	cracklike lesion on skin
Laceration	تقرح	torn or jagged wound
Macule	لطفة	flat, discolored spot on skin
Nodule	عقيدة	firm, solid mass larger than 0.5 cm

# Cyst كيسة

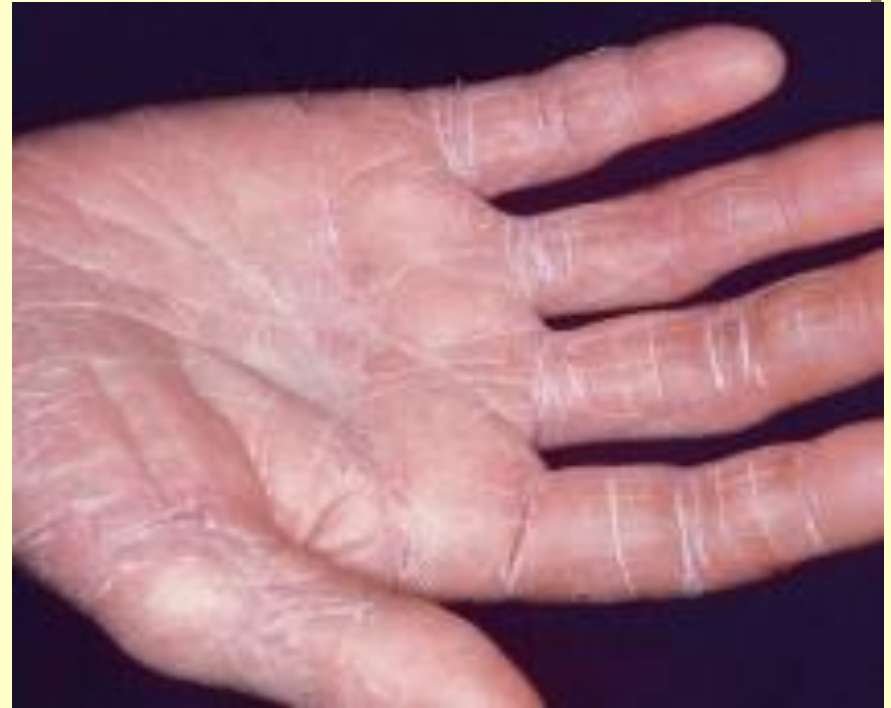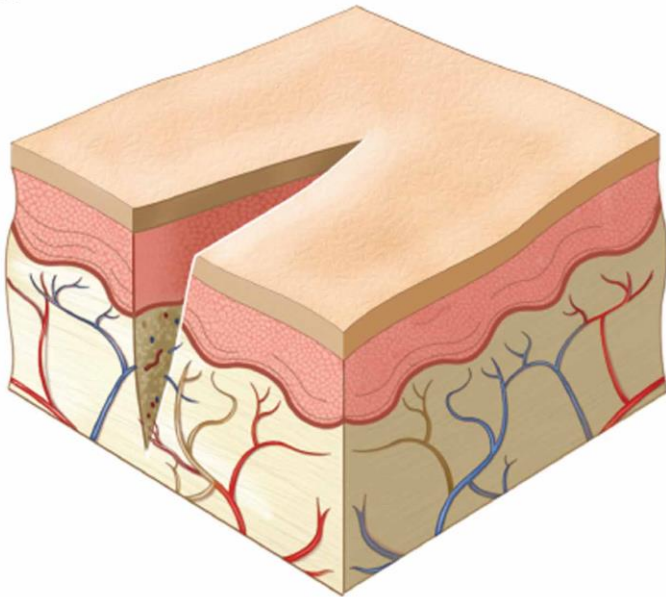


A) Cutaway view and B) photograph of a cyst.

# Fissure

شق

C

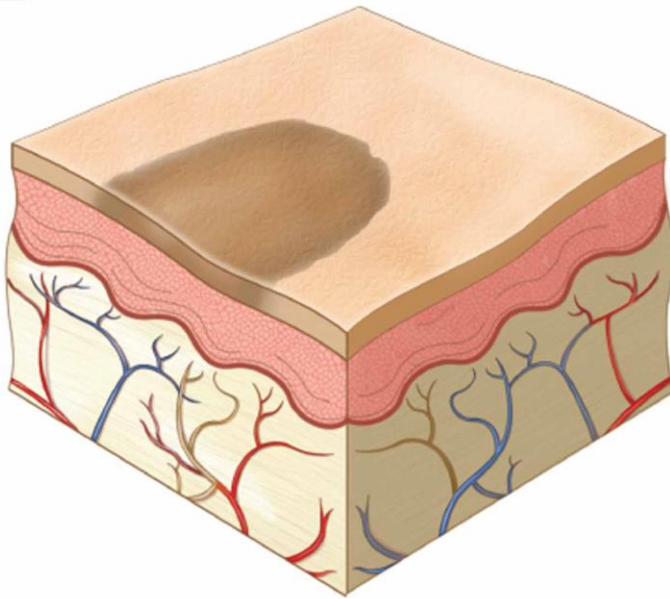


D

C) Cutaway view and D) photograph of a fissure.

# Macule لطفة

E



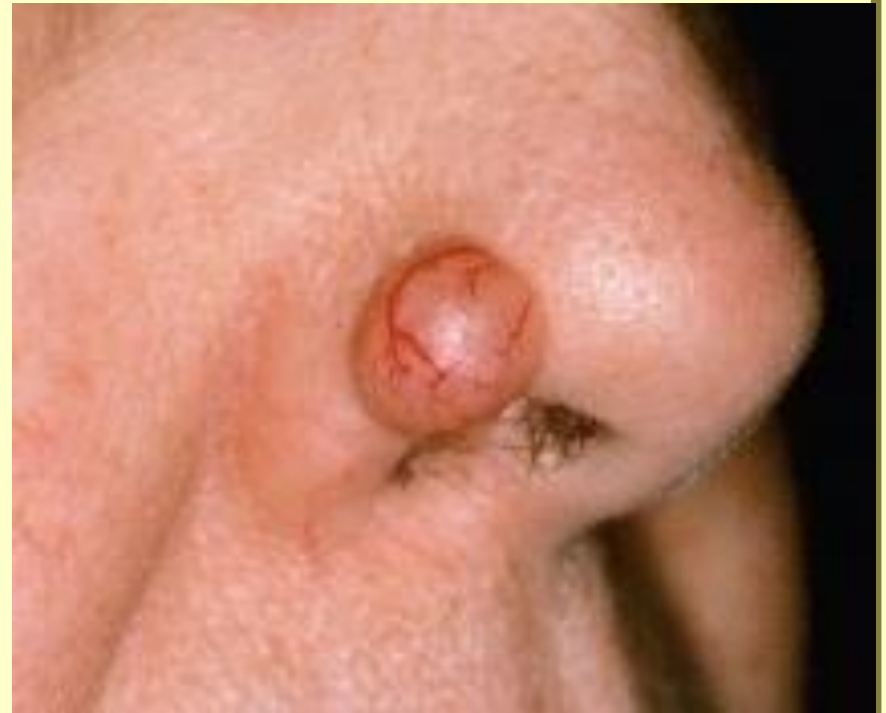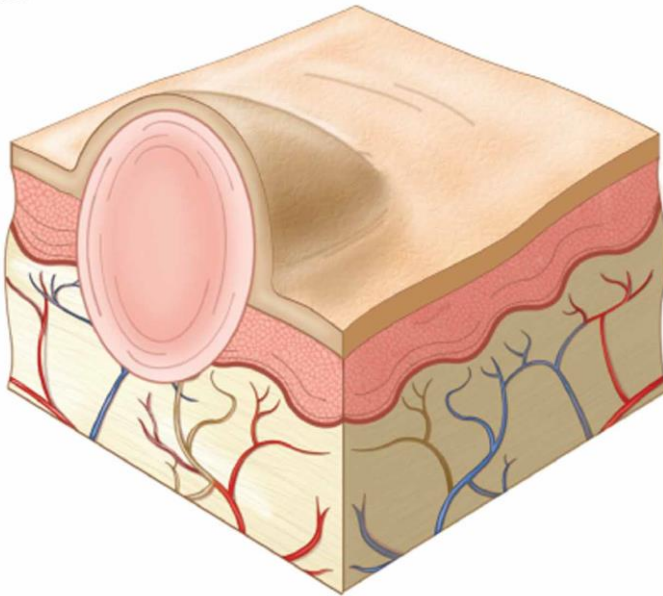
F

E) Cutaway view and F) photograph of a macule.

# Nodule

# عقيدة

G



H

G) Cutaway view and H) photograph of a nodule.

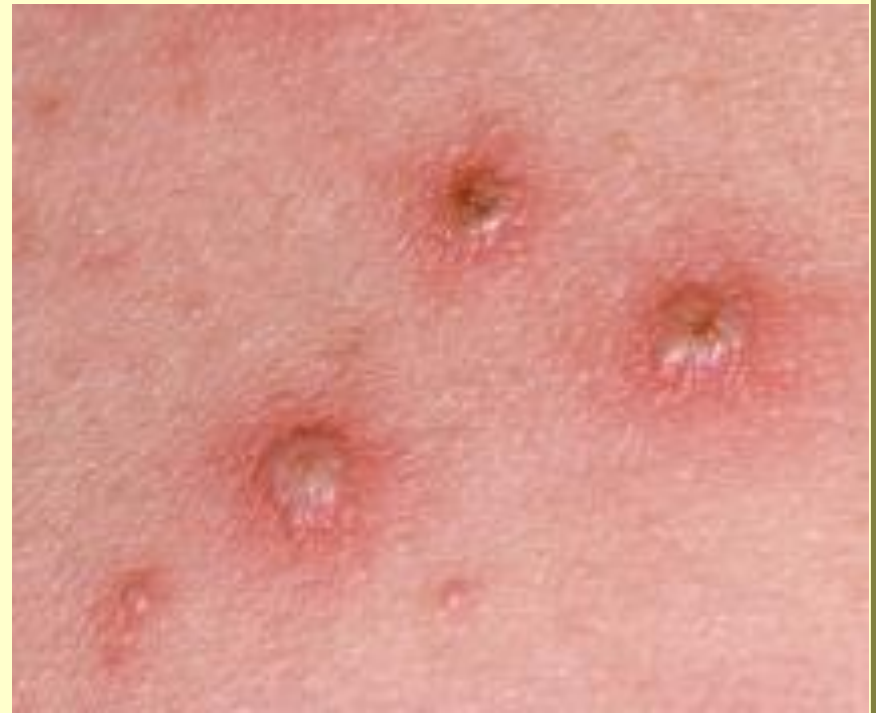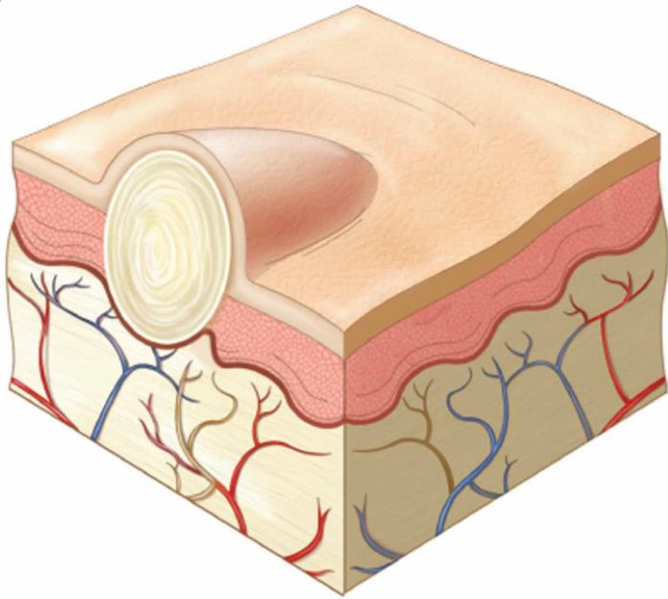


# Pathology – Surface Lesions

papule	small, solid raised spot smaller than 0.5 cm
pustule	raised spot on skin containing pus
ulcer	open sore in skin
vesicle	small, fluid-filled, raised spot; blister



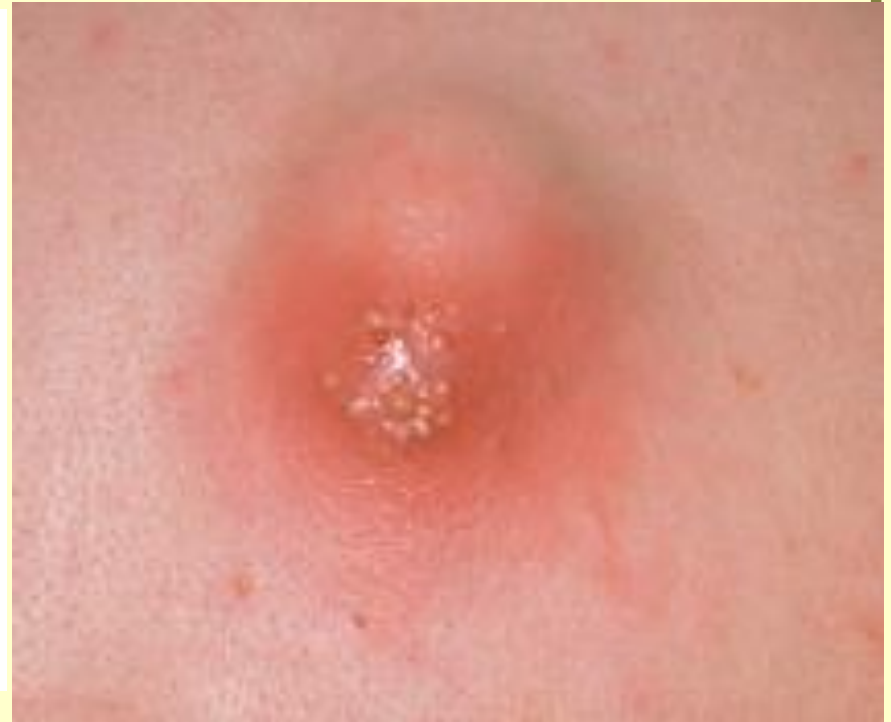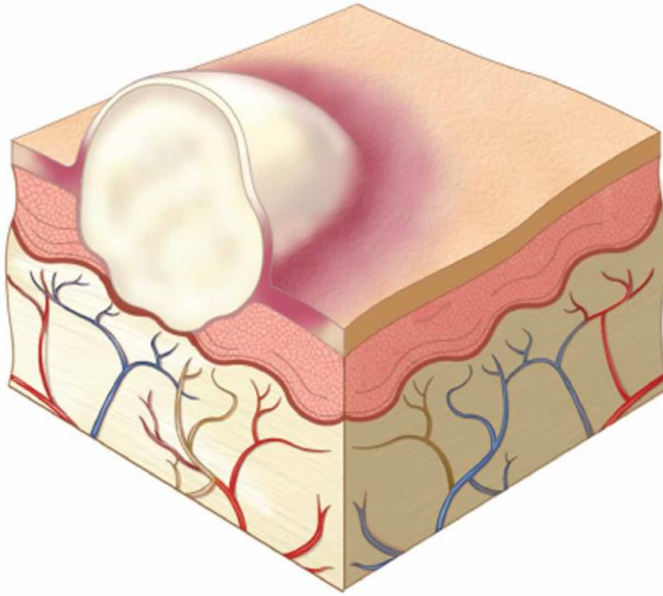
# Papule حطاطة



I) Cutaway view and J) photograph of a papule.

# Pustule      بثرة

K

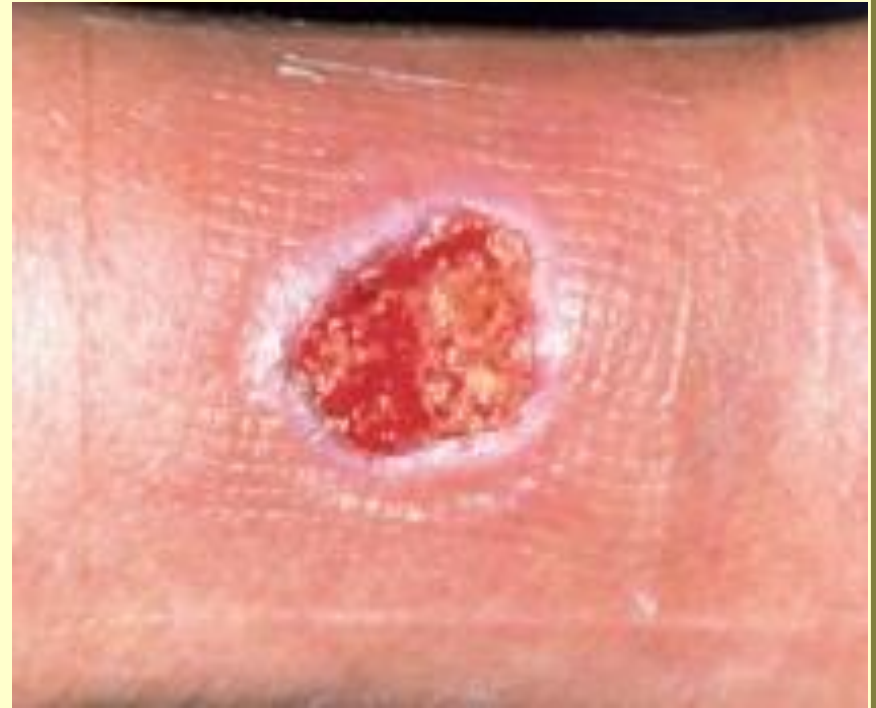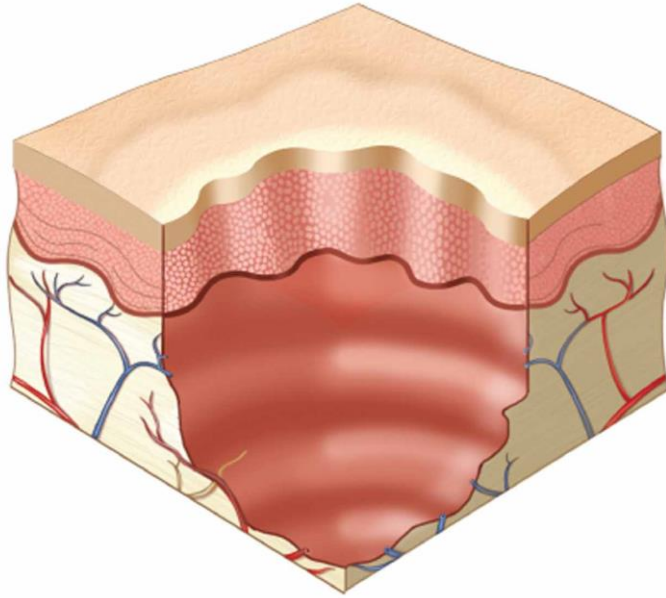


L

K) Cutaway view and L) photograph of a pustule.

# Ulcer قرحة

M

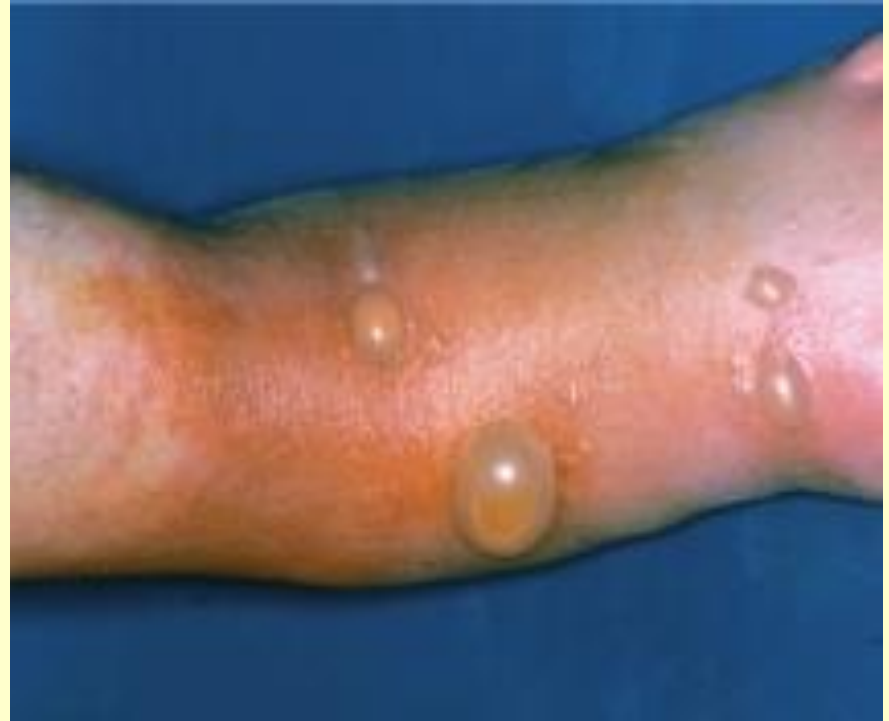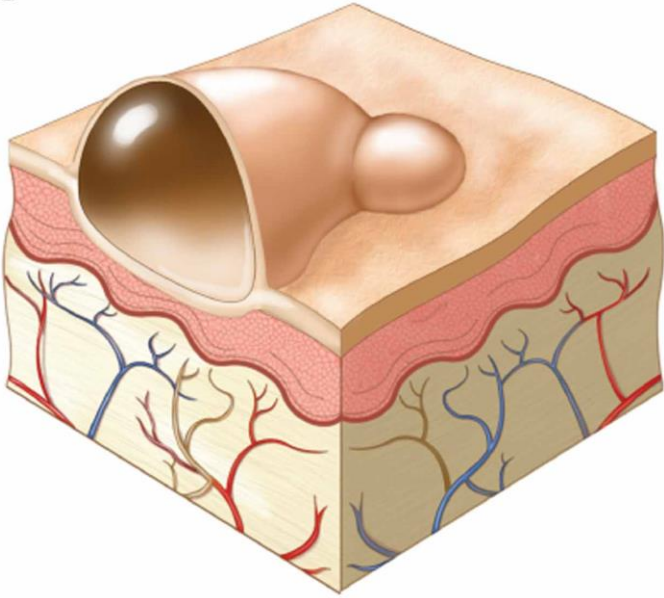


N

M) Cutaway view and N) photograph of an ulcer.

# Vesicle حويصل

O

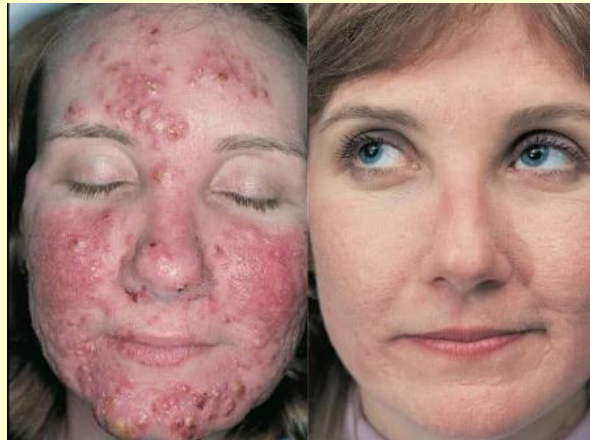

P

O) Cutaway view and P) photograph of a vesicle.

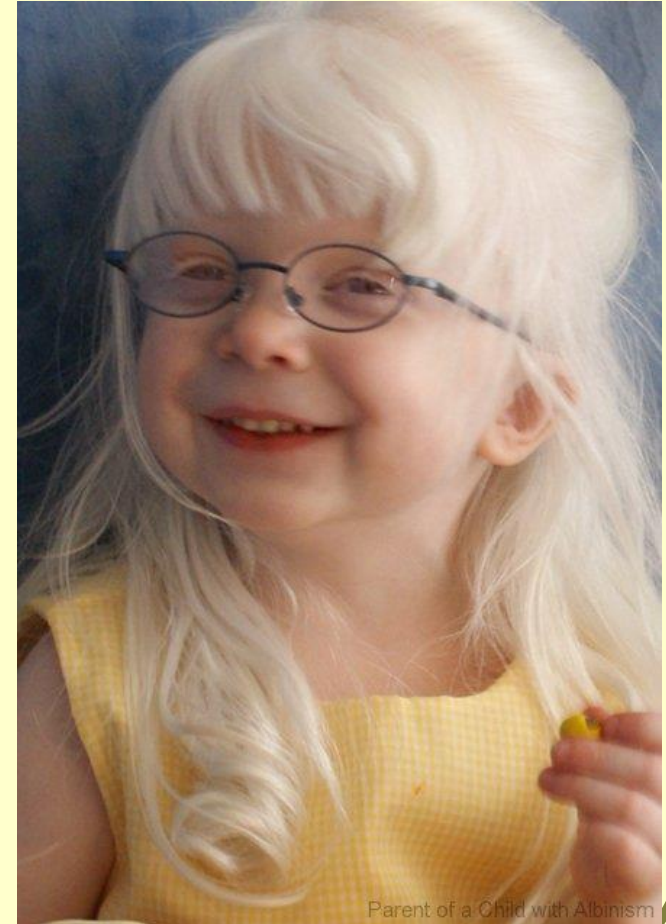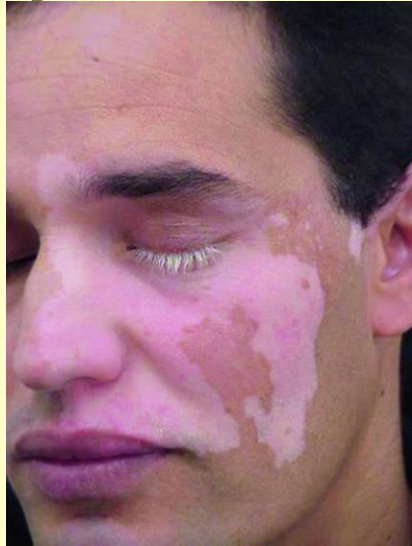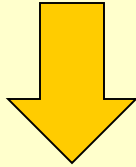
# Pathology of the Skin

Abscess خراج	collection of pus in skin
acne vulgaris العد الشائع	common form of teenage acne with comedo, papules, and pustules
Albinism النصوع	genetic condition; unable to make melanin; white hair and skin, and red eyes





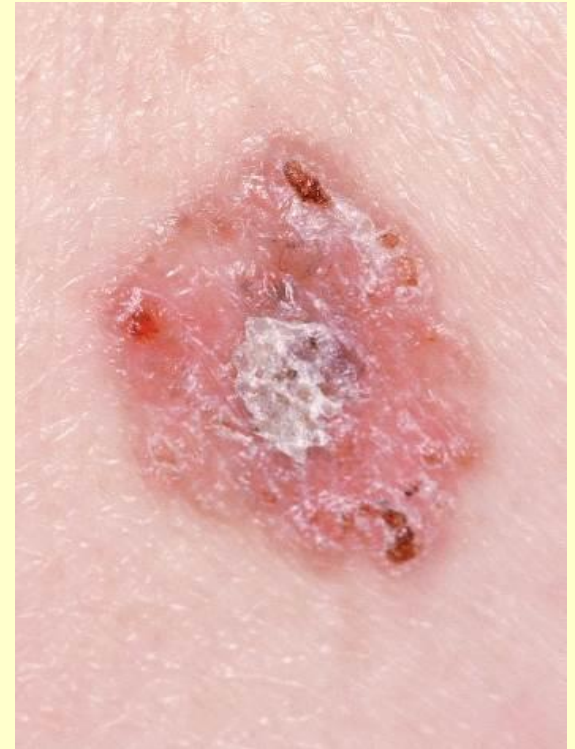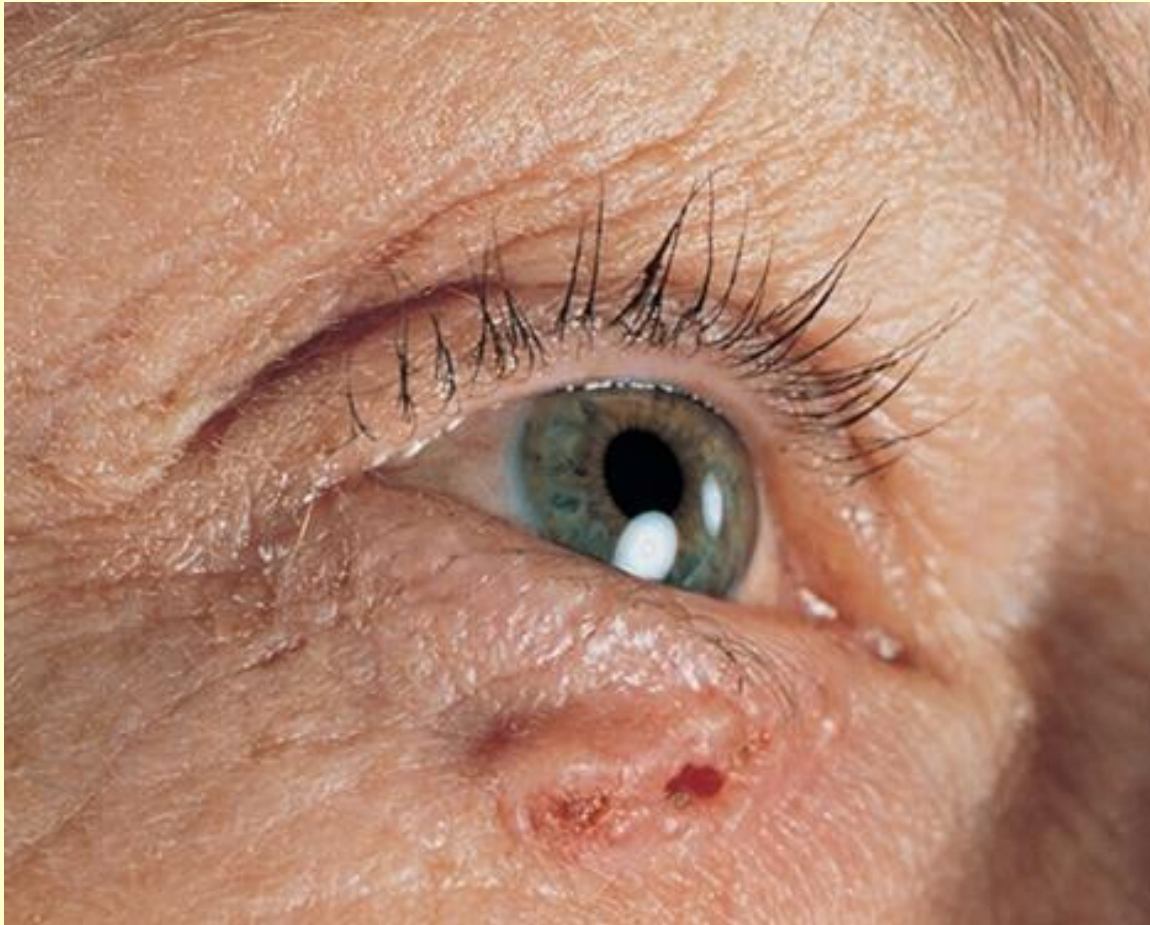# النصوع – albinism – البهاق Vitiligo



# Pathology of the Skin

Basal Cell Carcinoma(BCC) السرطانة قاعدية الخلايا	cancerous tumor in basal cell layer; common cancer; rarely metastasizes
Squamous Cell carcinoma(SCC) السرطانة شائكة الخلايا	cancerous tumor in squamous cell layer; common cancer; can metastasizes
Burn	caused by fire, electricity, ultraviolet light, or chemicals; percentage of skin burned is estimated by Rule of Nines

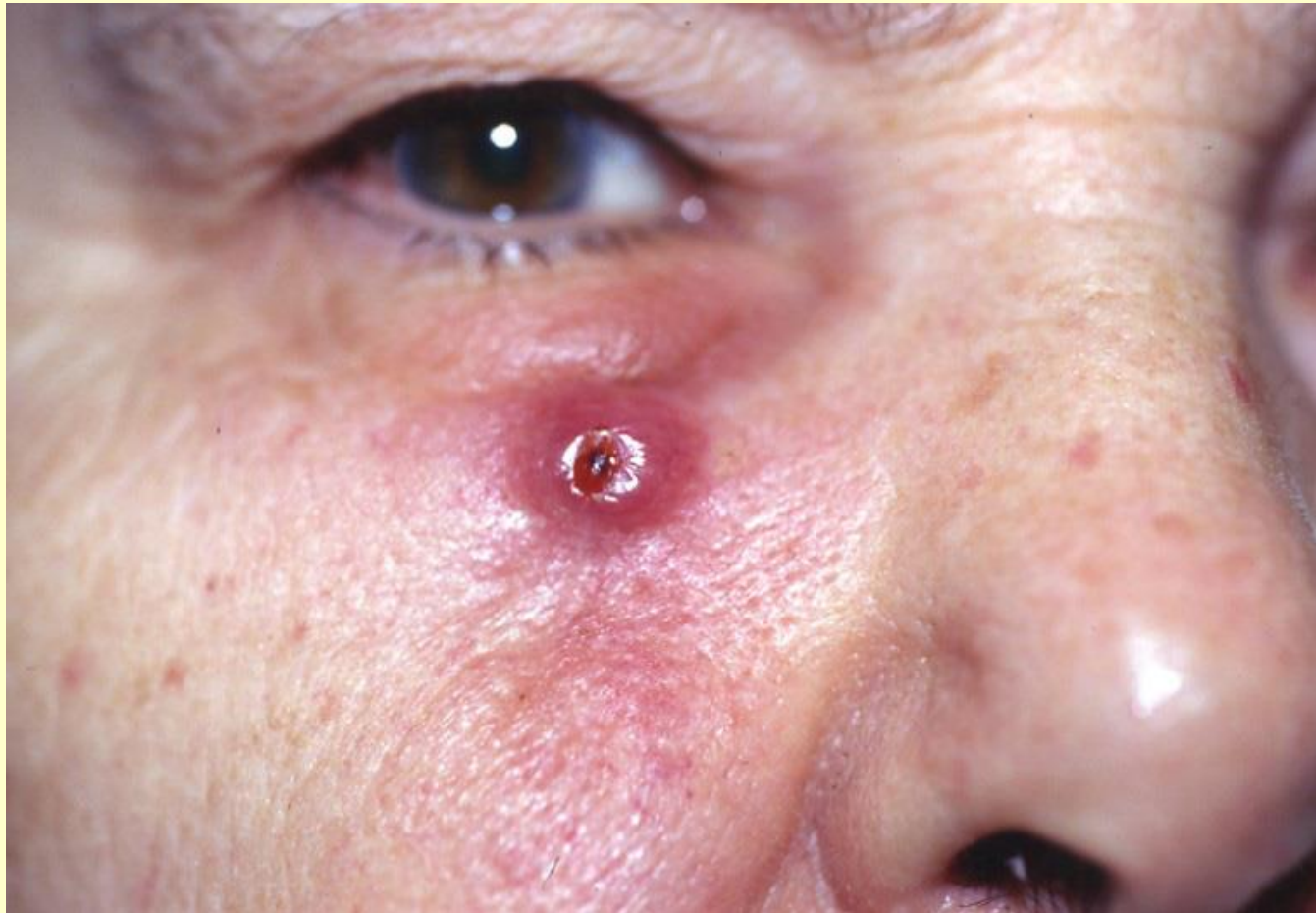

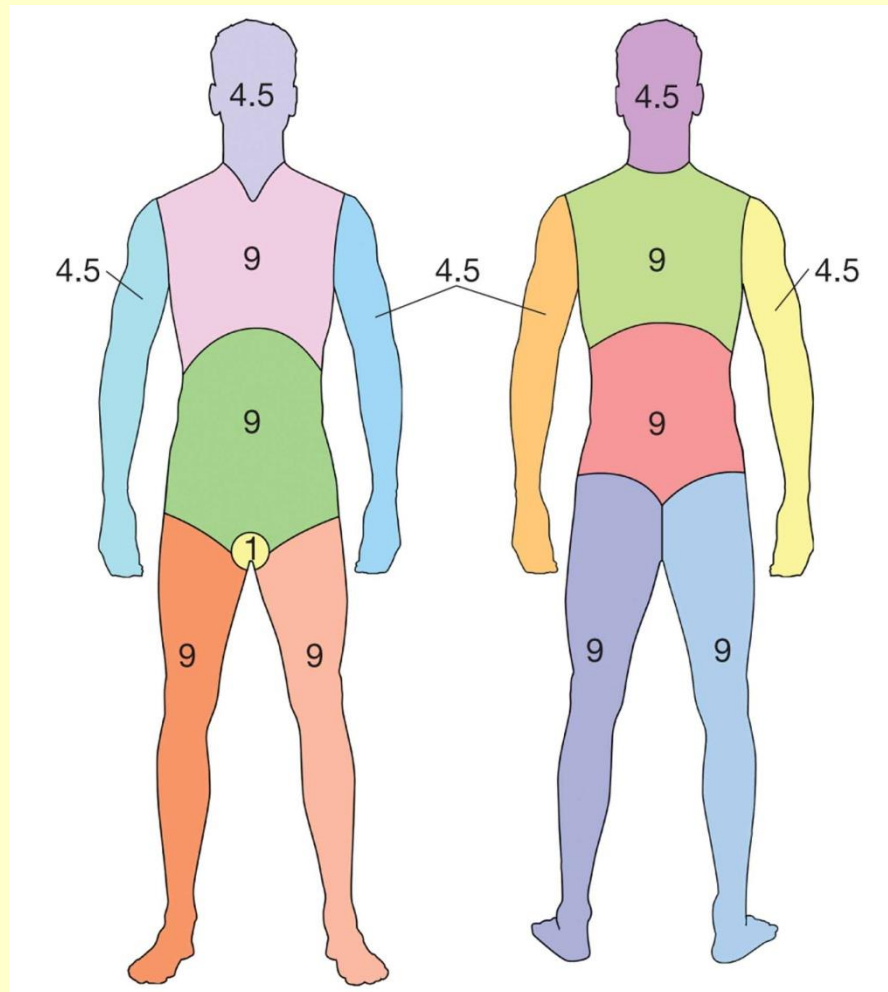


Basal cell carcinoma. A frequent type of skin cancer that rarely metastasizes.

# Squamous cell carcinoma

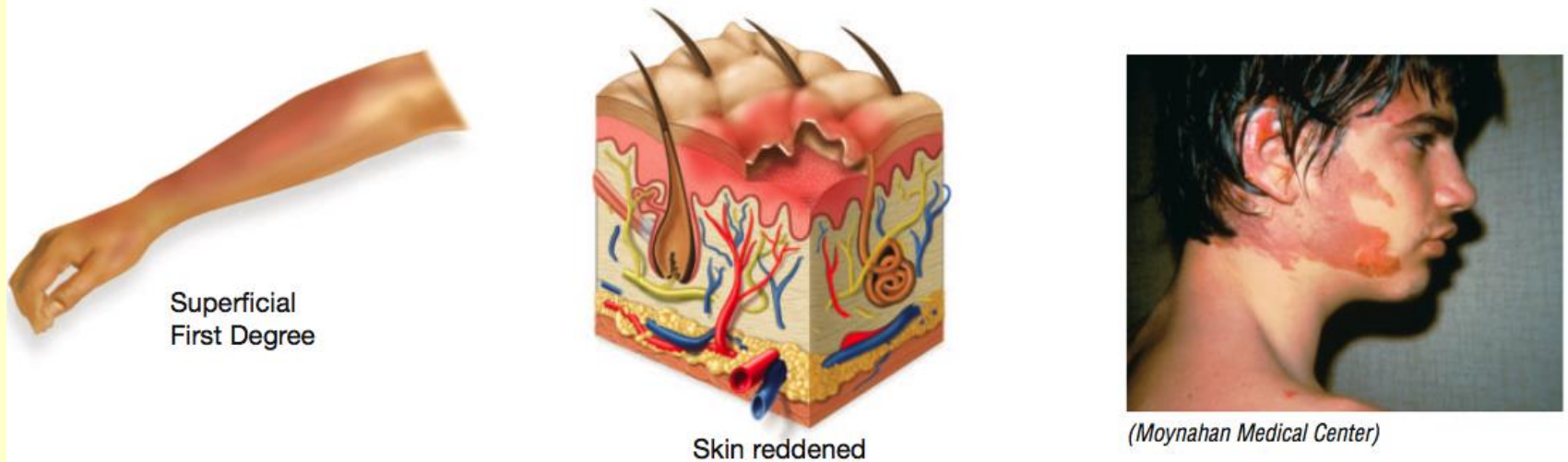
السرطانة شائكة الخلايا





Rule of Nines. A method for determining percentage of body burned.  
Each differently colored section represents 9% of the body surface.

# First Degree Burn

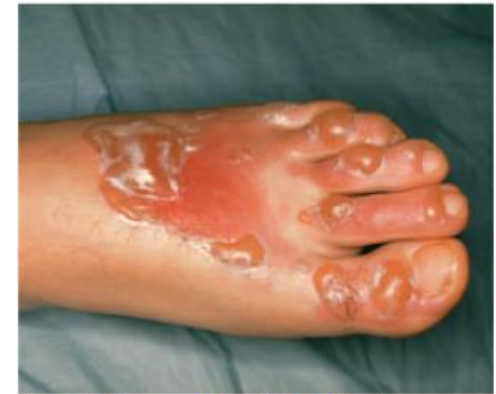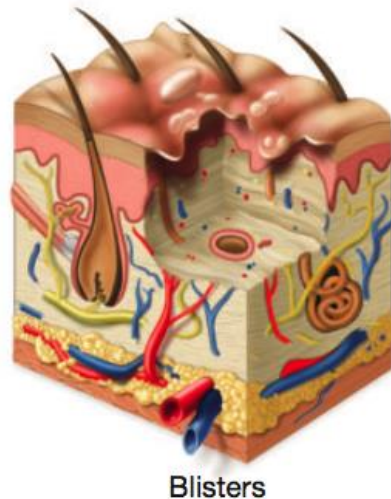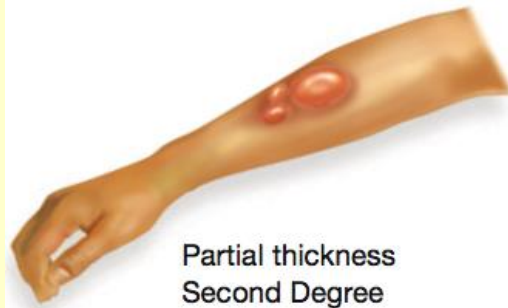


First degree  
burn

skin reddened and painful; no blisters;  
damage to epidermis



# Second Degree Burn

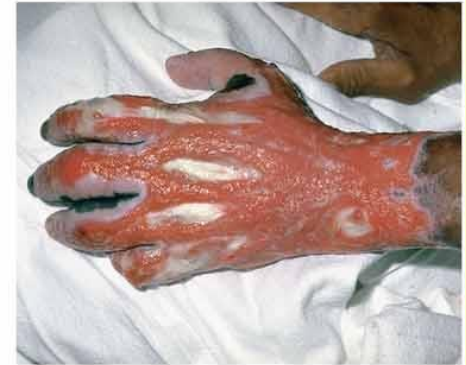
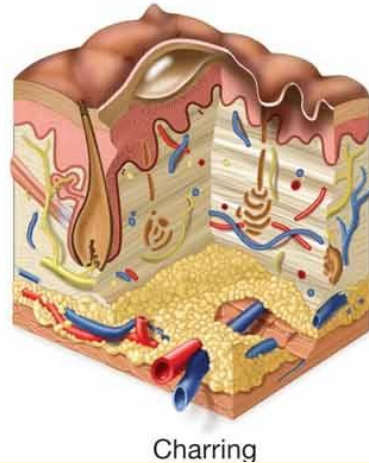
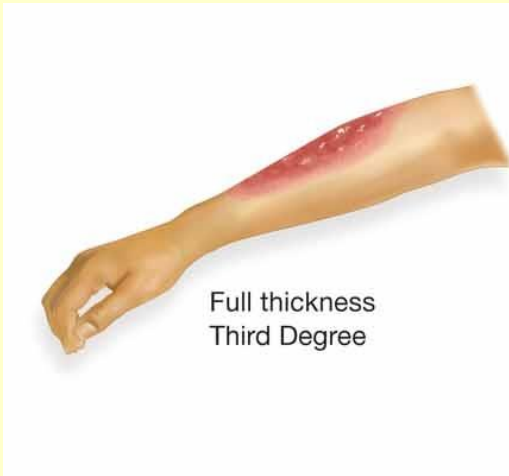(Charles Stewart MD FACEP, FAAEM)

Second  
degree burn

skin reddened and painful with blisters;  
damage to epidermis and dermis

# Third Degree Burn

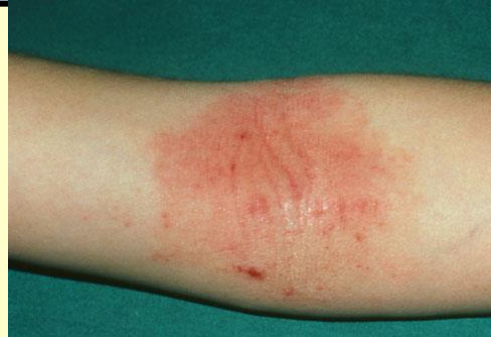

Third degree  
burn

skin charred; epidermis and dermis  
burned away; subcutaneous layer  
exposed

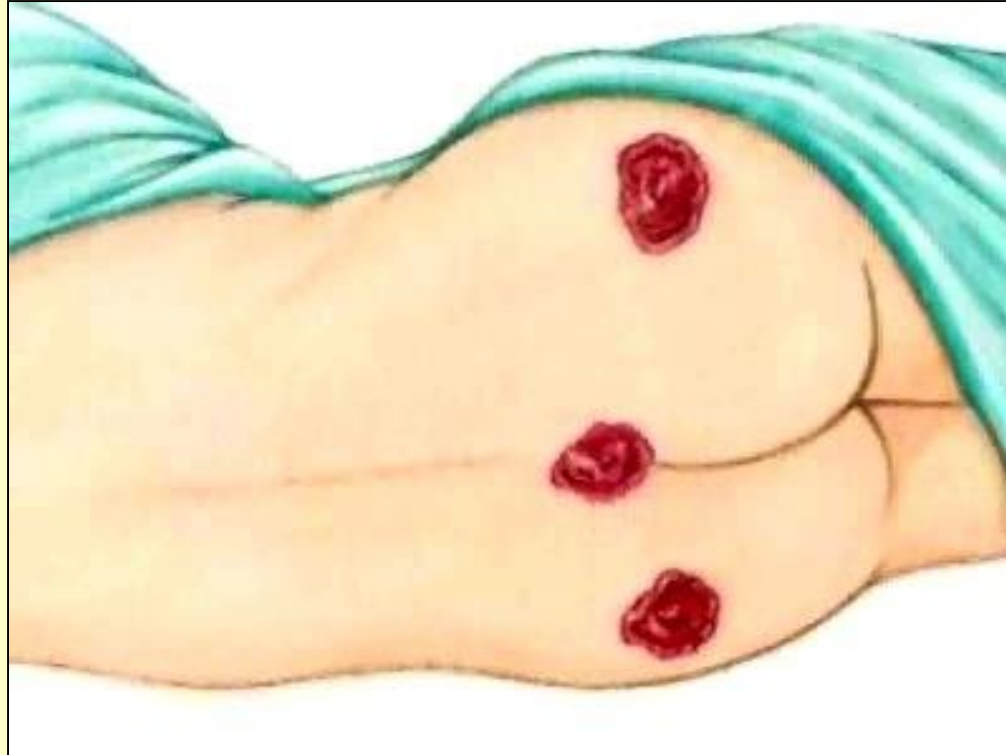
# Pathology of the Skin

Cellulitis التهاب النسيج الخلوي	diffuse acute infection of connective tissue of skin
decubitus ulcer قرحة الاستلقاء	open sore caused by pressure over bony prominences; caused by loss of blood flow to skin
eczema	superficial dermatitis; redness, vesicles, itching, and crusting



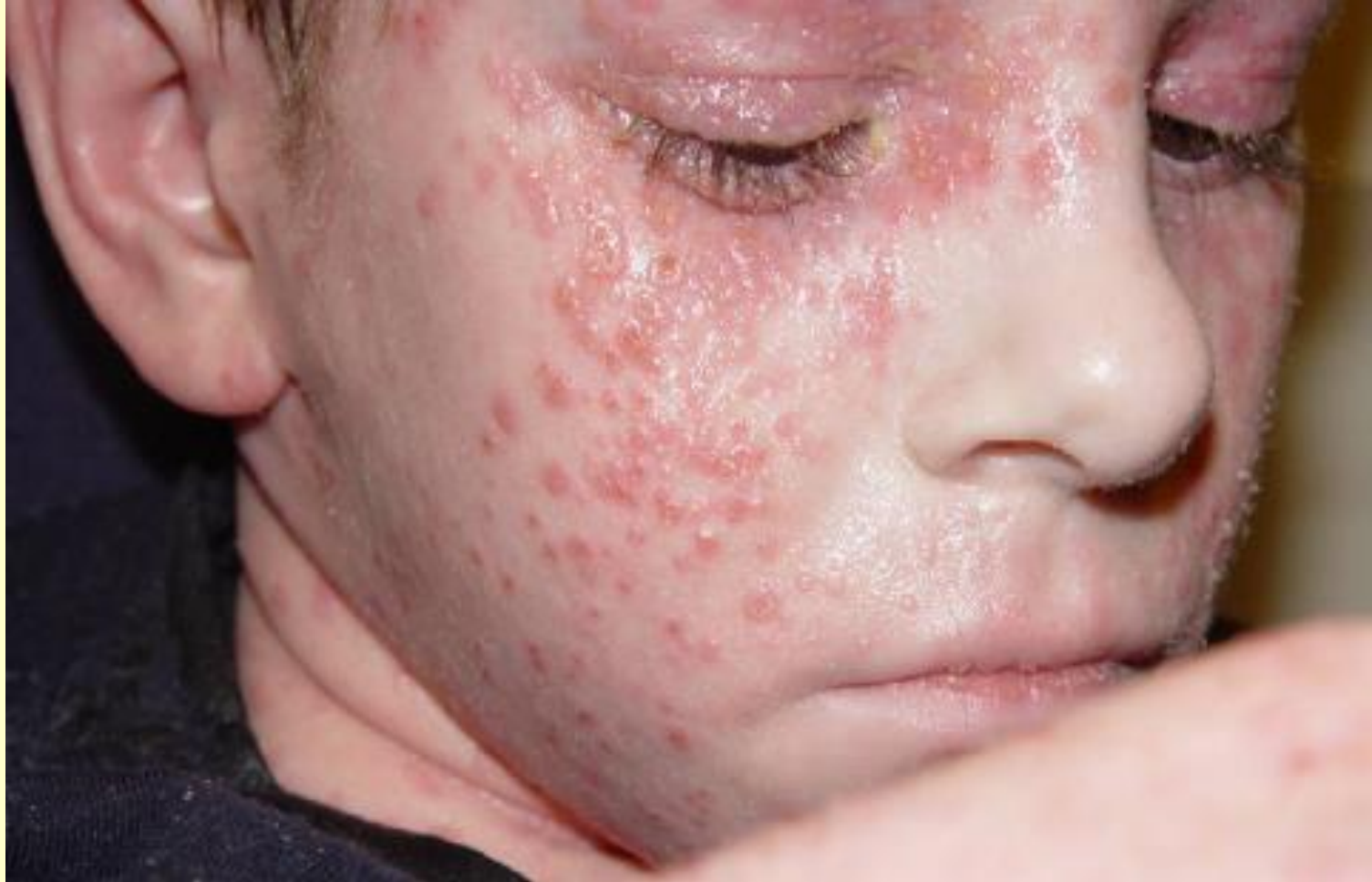

# Decubitus Ulcer قرحة الاستلقاء



Click [here](#) to view a video on decubitus ulcers.

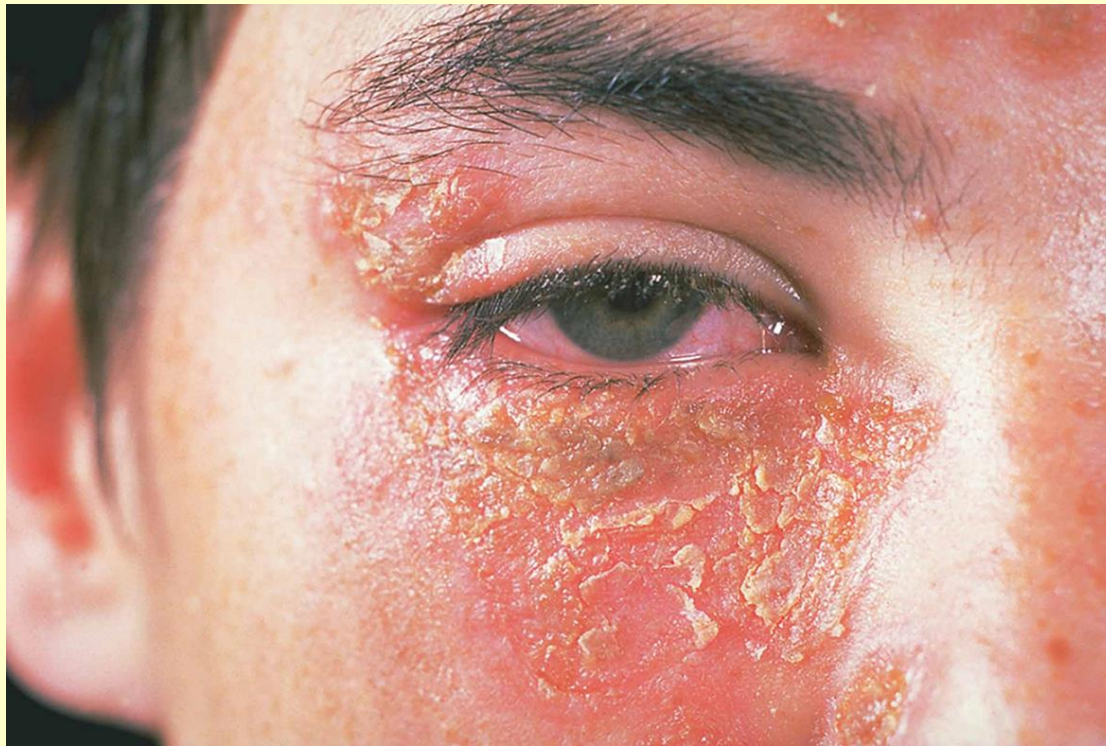# Eczema



# Pathology of the Skin

Impetigo القوباء

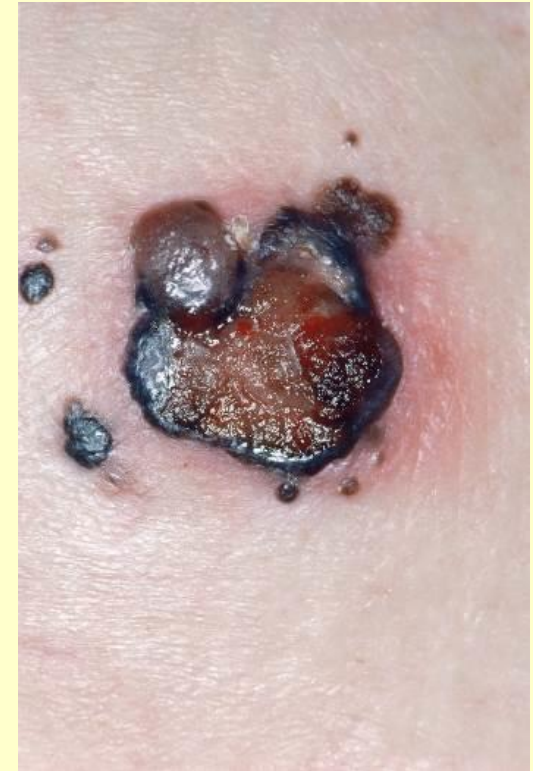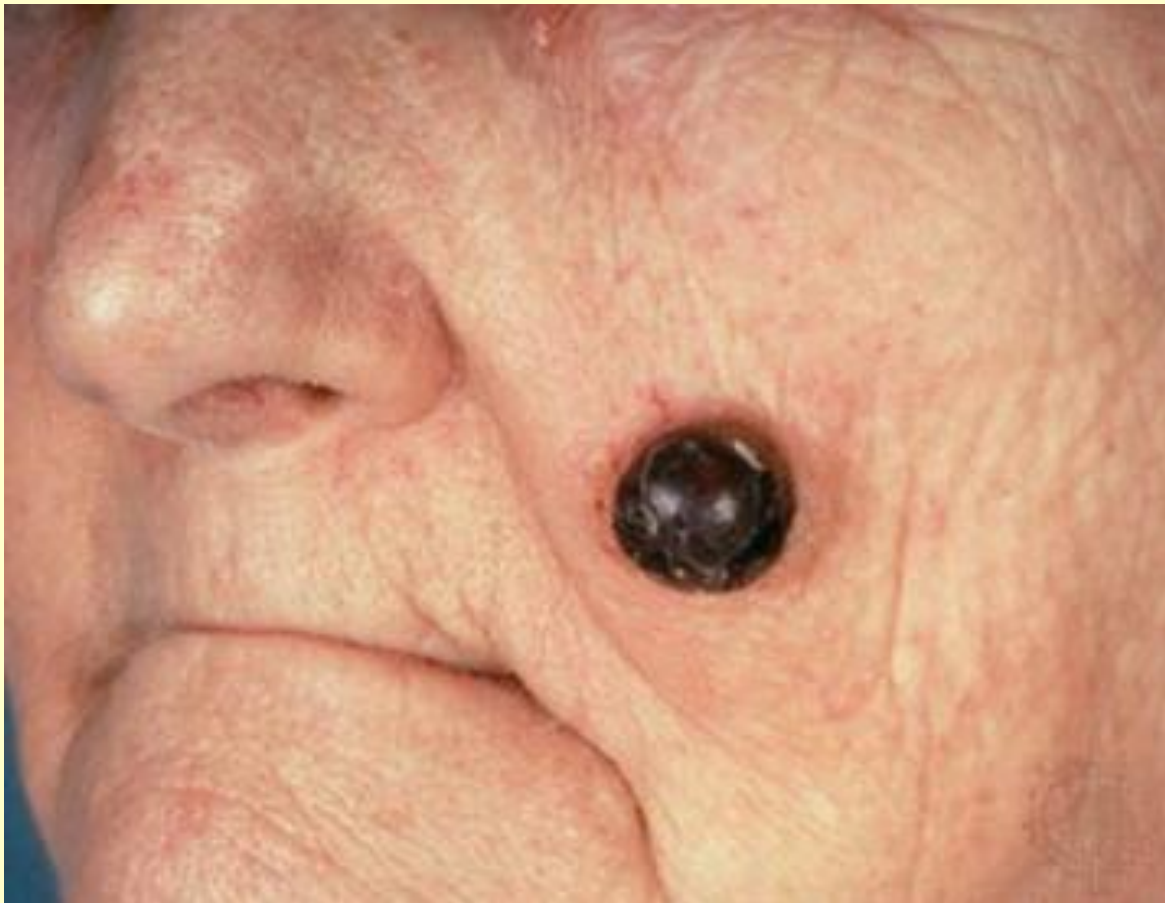highly infections bacterial infection with pustules that rupture and crust over



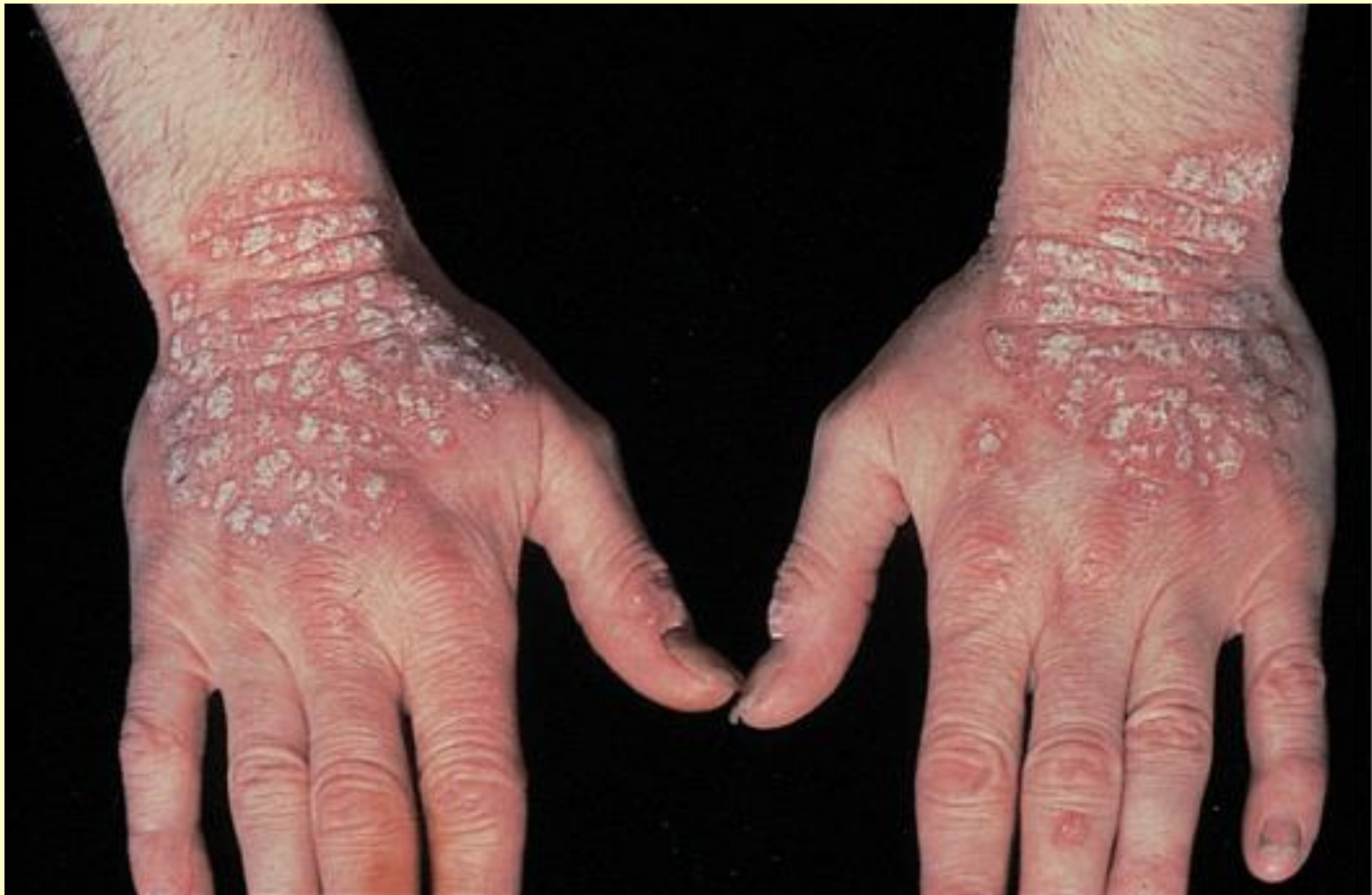# Pathology of the Skin

malignant melanoma (MM) الملانوما الخبيثة	dangerous form of cancer; begins in melanocytes; quickly metastasizes
Pediculosis داء القمل	lice infestation
Psoriasis الصدف	chronic inflammatory condition with papules forming “silvery scale” patches
Scabies الجرب	mite infestation





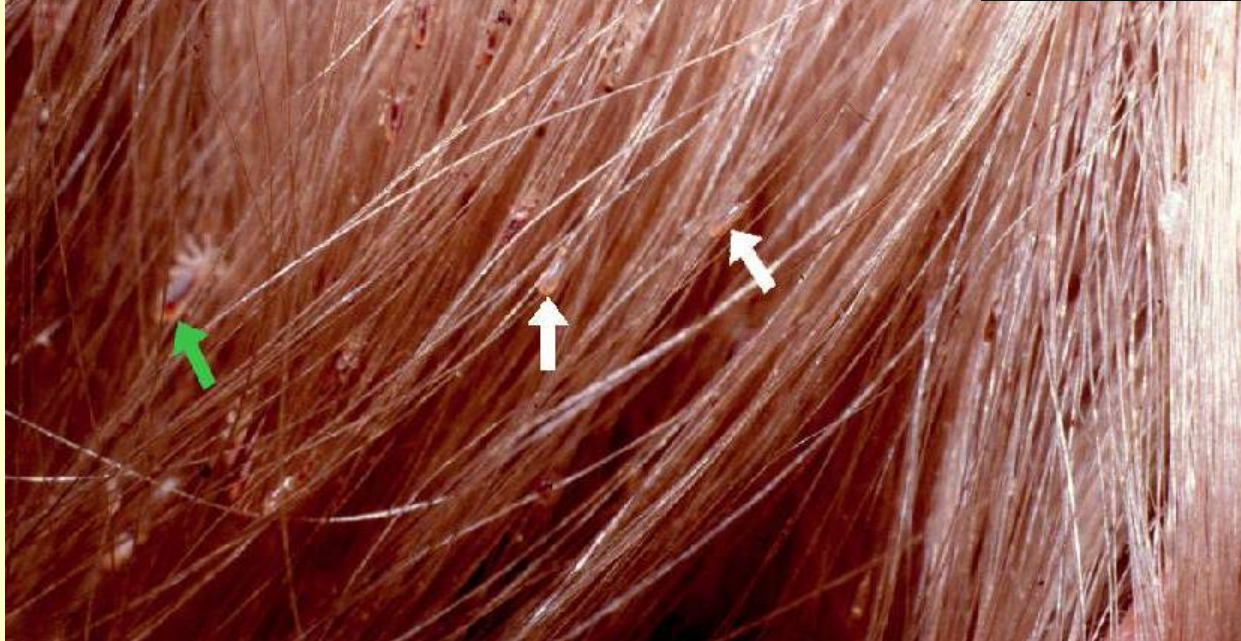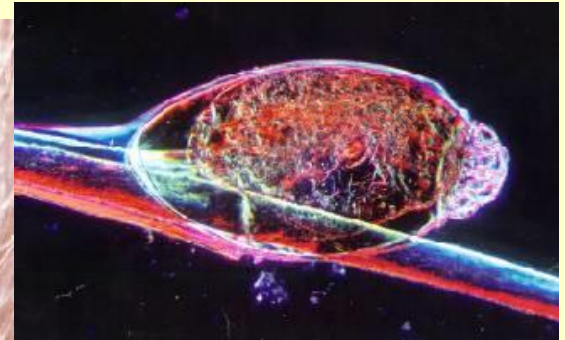

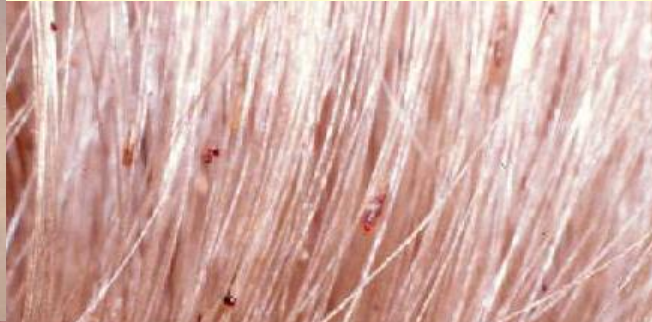Malignant melanoma. This tumor demonstrates the highly characteristic color of this tumor.



Psoriasis. This photograph demonstrates the characteristic white skin patches of this condition.

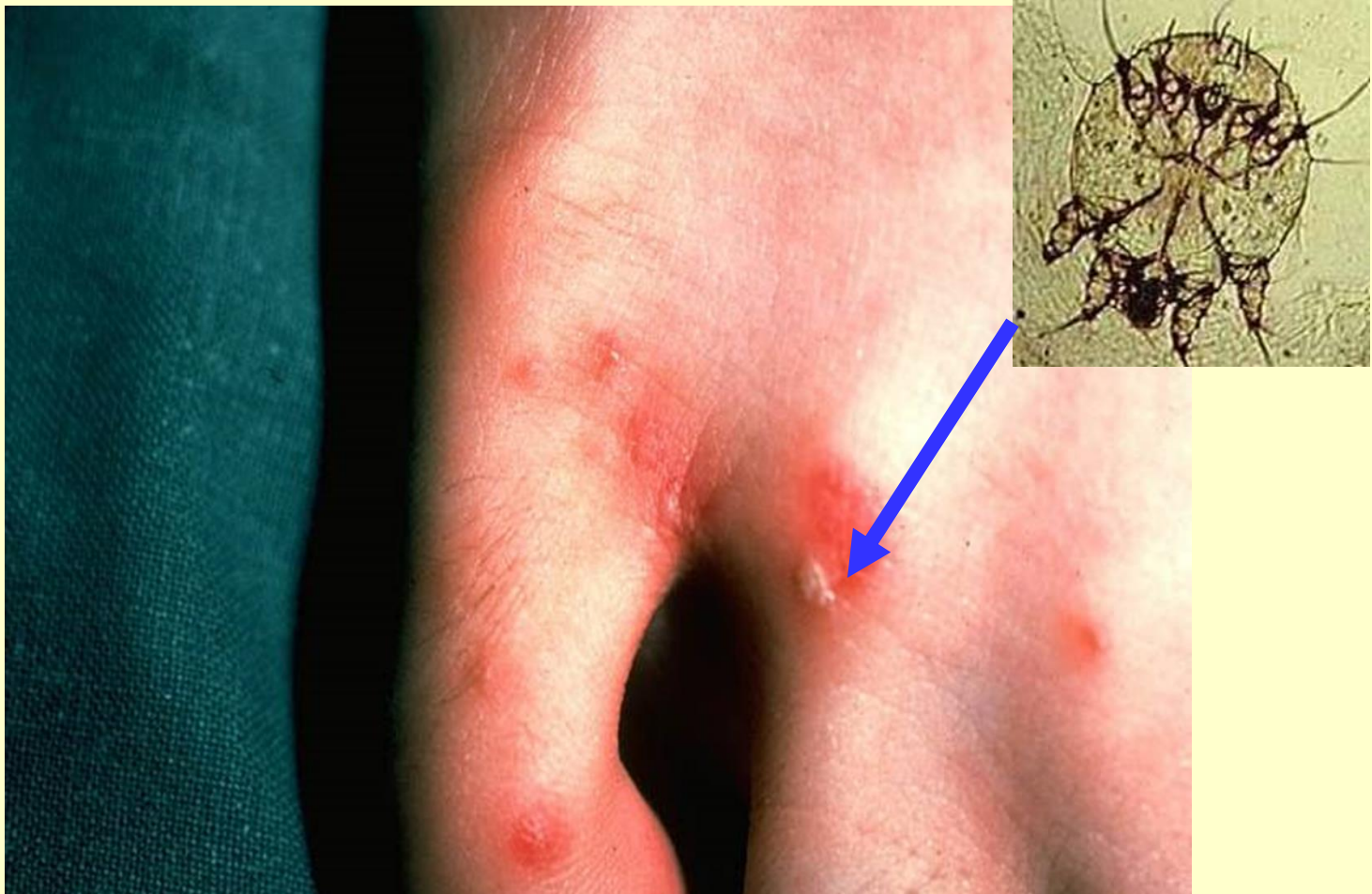

# Pediculosis



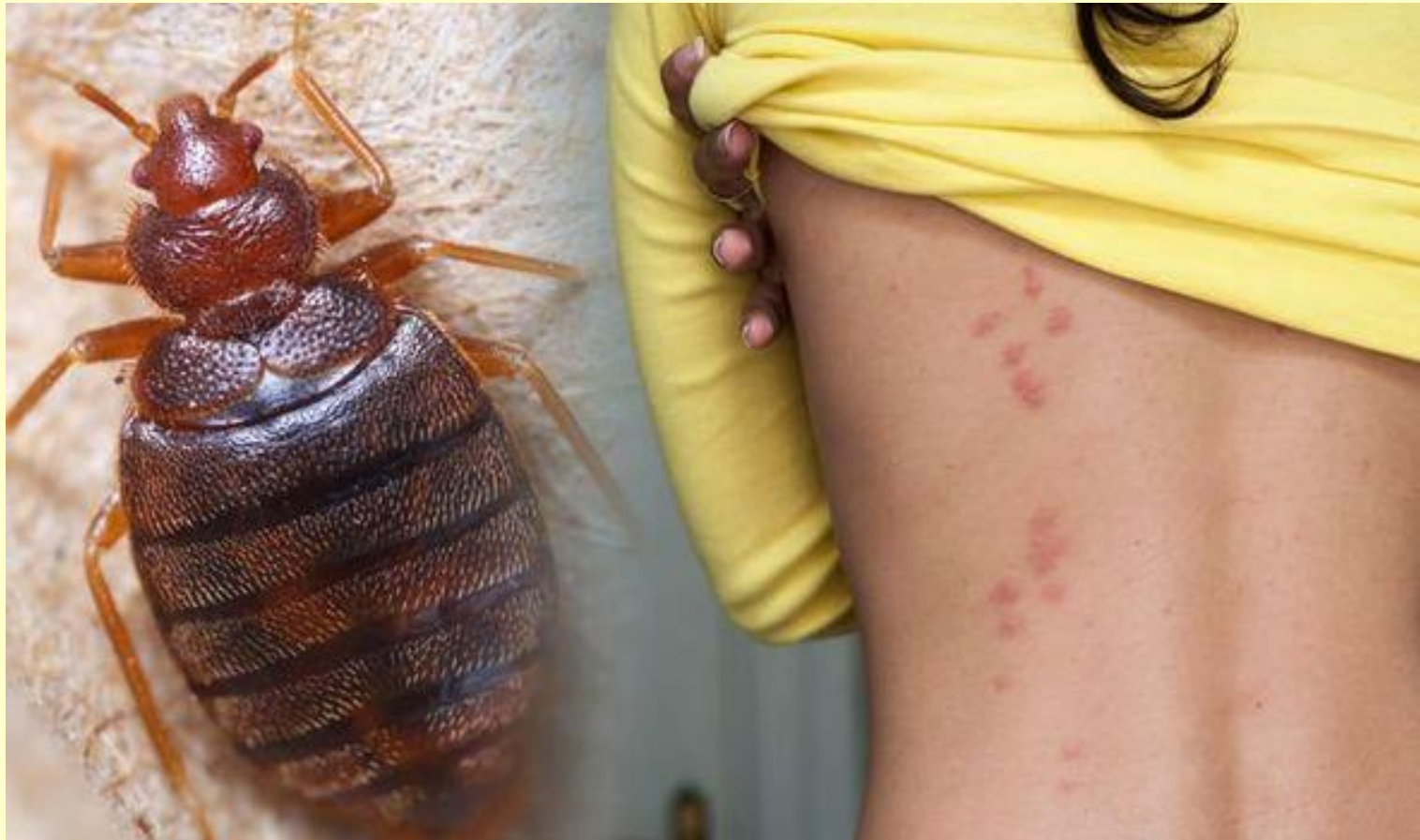# Scabies

# الجرب





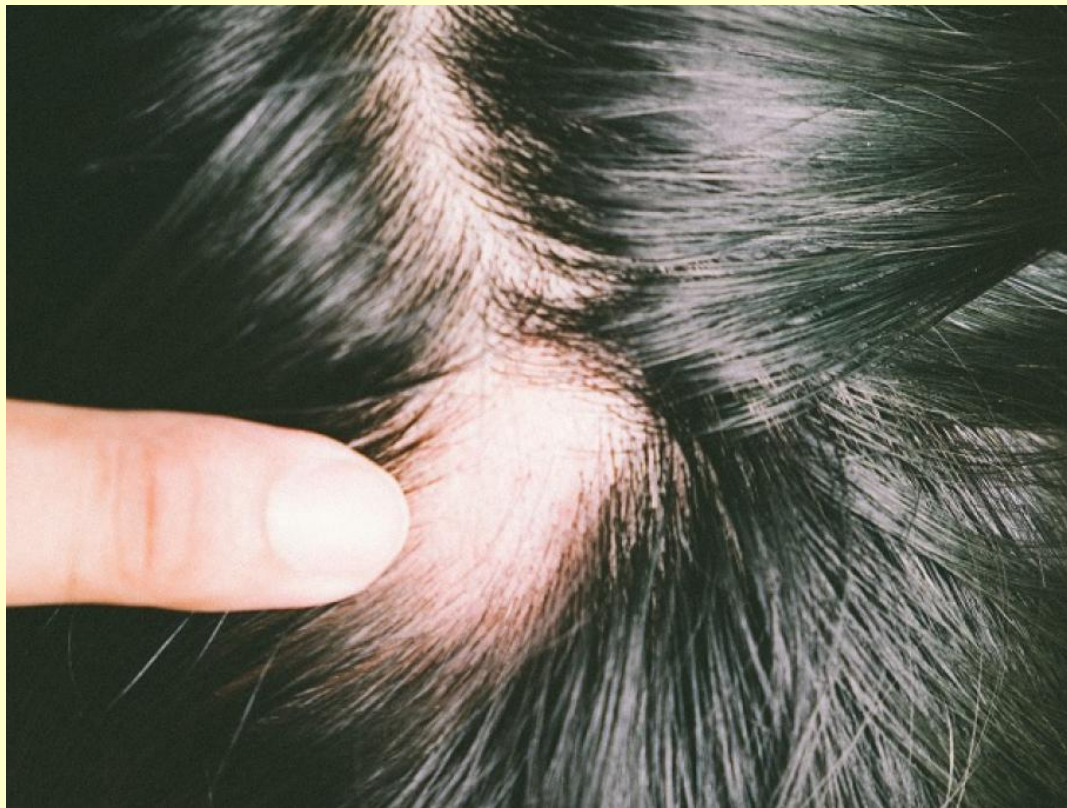# بق الفراش Bed Bugs



# Pathology of the Hair

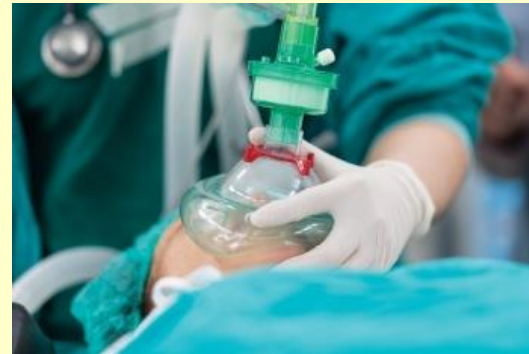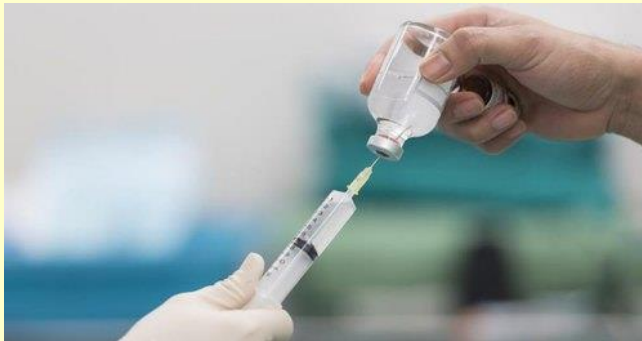Alopecia الثعلبة

absence or loss of hair; baldness



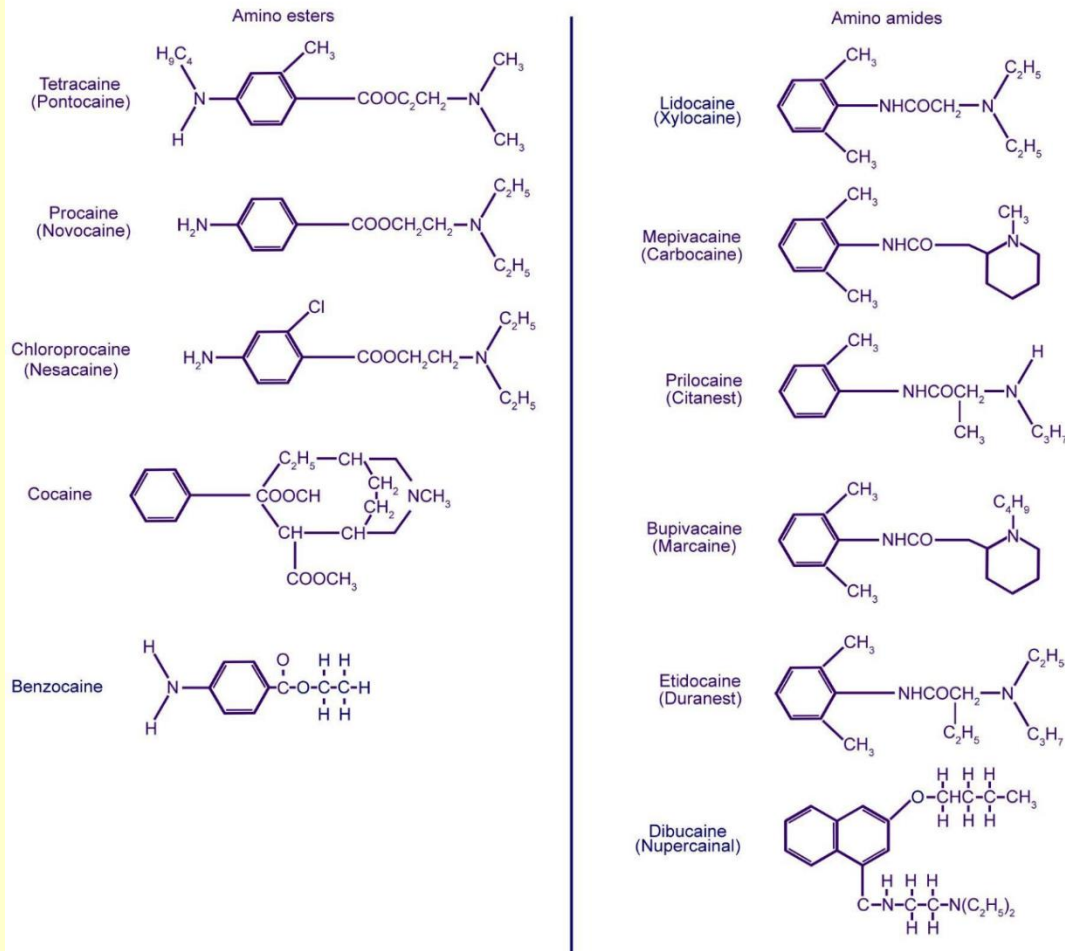
# Integumentary Pharmacology

anesthetics	deaden pain	Xylocaine, Novocain
antibiotics	kill bacteria	Neosporin
antifungals	kill fungi	Monistat, Lotrimin
antiparasitics	kill mites or lice	Kwell, Nix



# Anesthetics

Chemical structure of local anesthetics



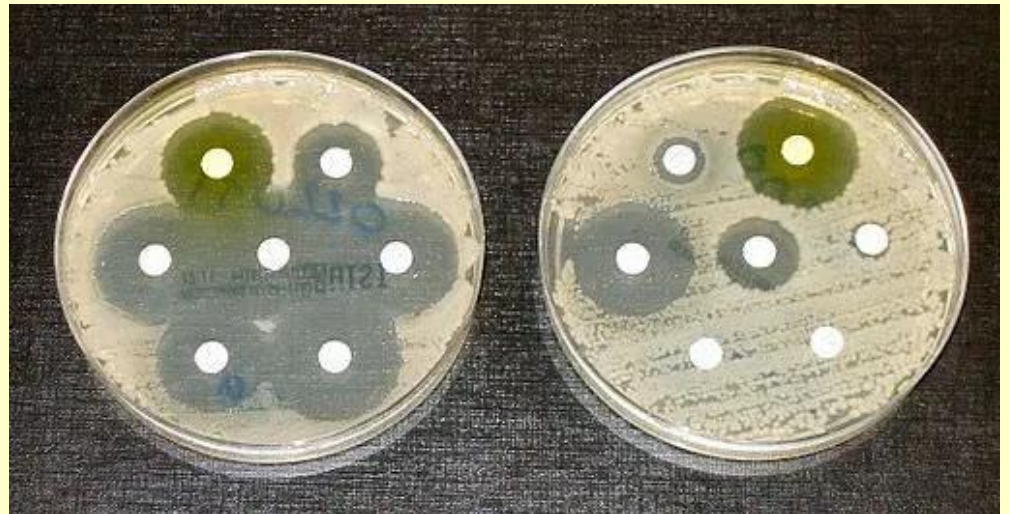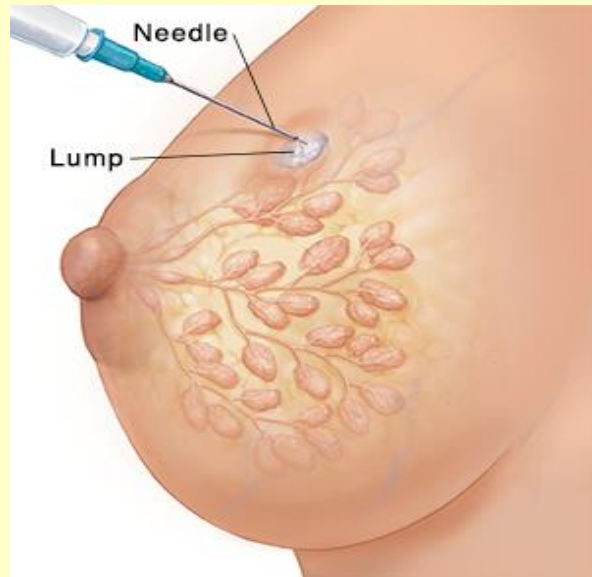


# Integumentary Pharmacology

antipruritics	reduce severe itching	Benadryl, Caladryl
antiseptics	kill bacteria	isopropyl alcohol, hydrogen peroxide
anti-virals	treat herpes simplex infection	Valtrex, Zovirax
corticosteroid cream	powerful anti-inflammatory	Cortaid; Kenalog

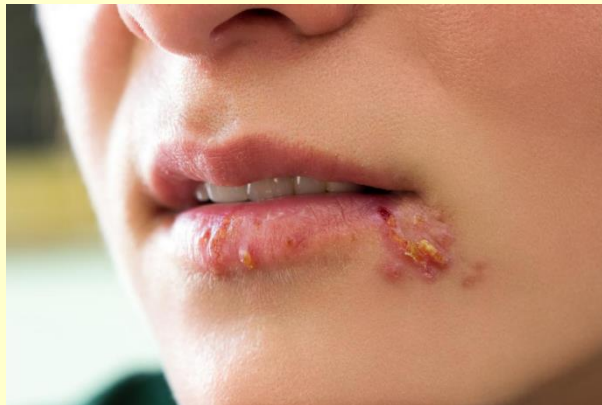# Integumentary Abbreviations

BX, bx	biopsy
C&S	culture and sensitivity

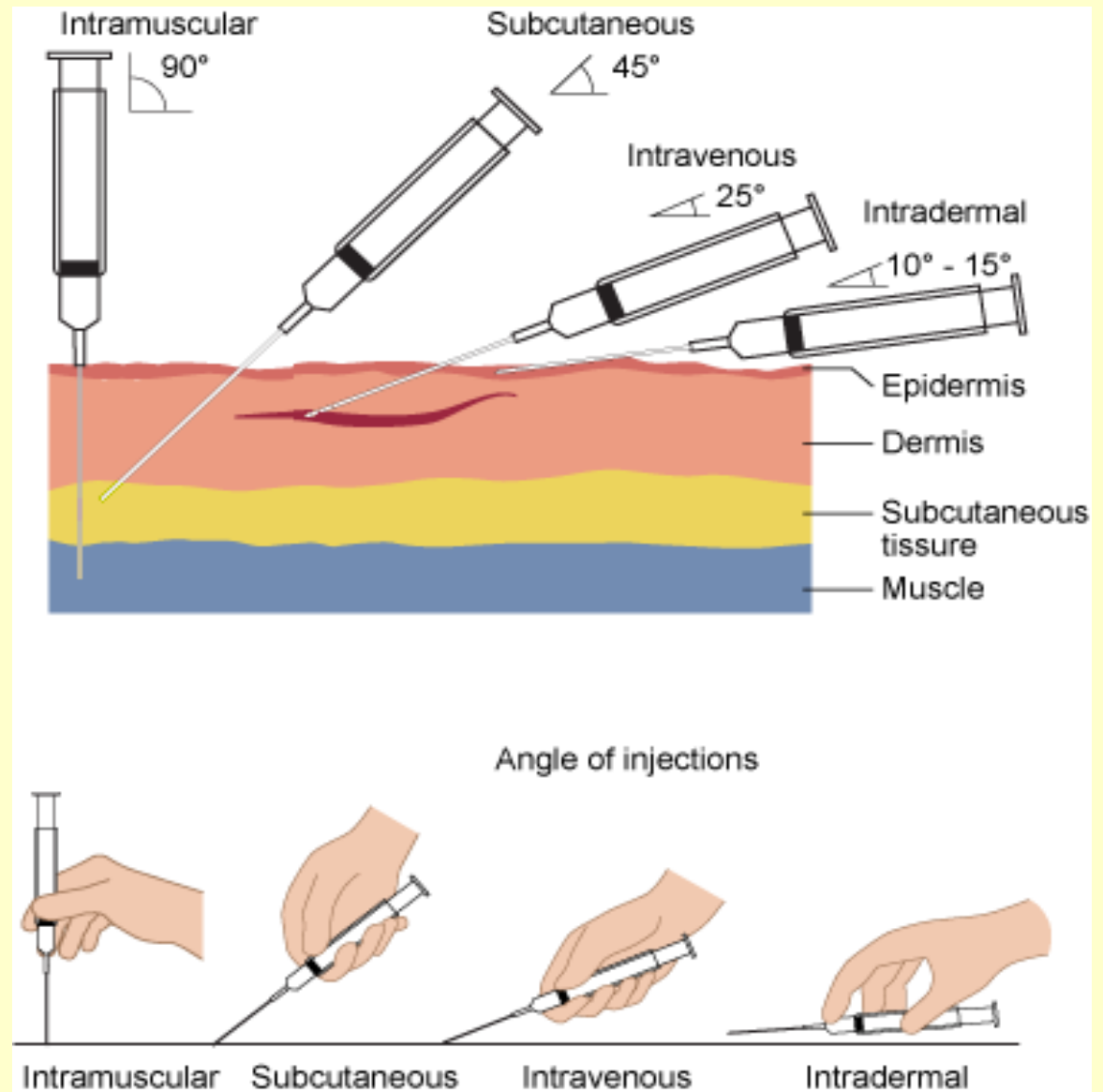
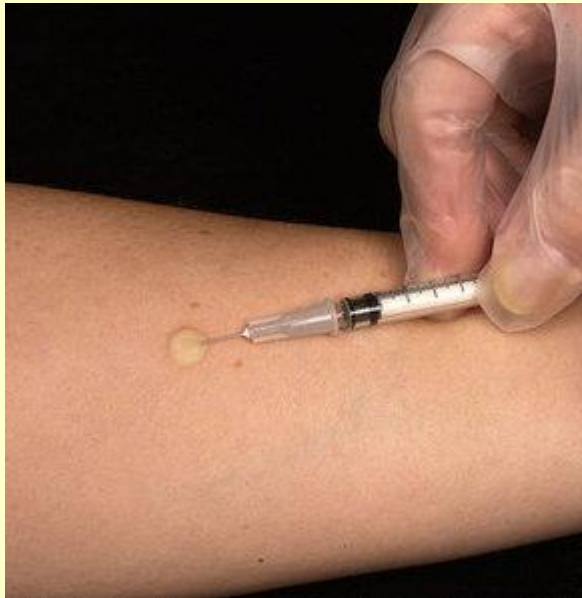

# Integumentary Abbreviations

HSV	herpes simplex virus
MM	malignant melanoma
SCC	squamous cell carcinoma



# Types of injection

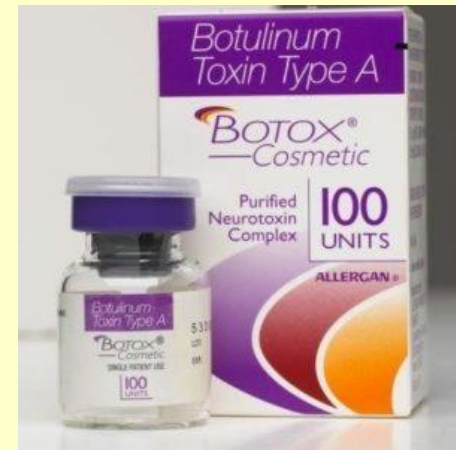
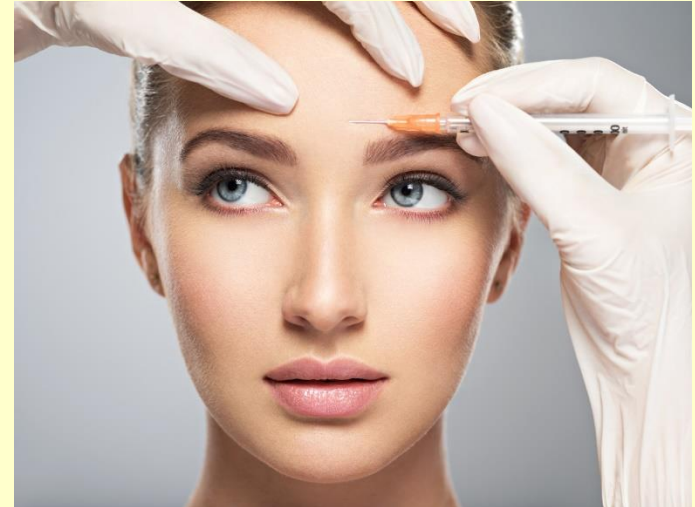
# New trends in cosmetology

- Botulinum toxin
- Fillers
- Hair & Tatoo removal by Laser
- Mesotherapy
- Liposuction
- HIFU: for face lift & remodeling
- Threads lift
- PRP: Platelet Rich Plasma: Hair loss & rejuvenation

# Botulinum toxin (BOTOX)

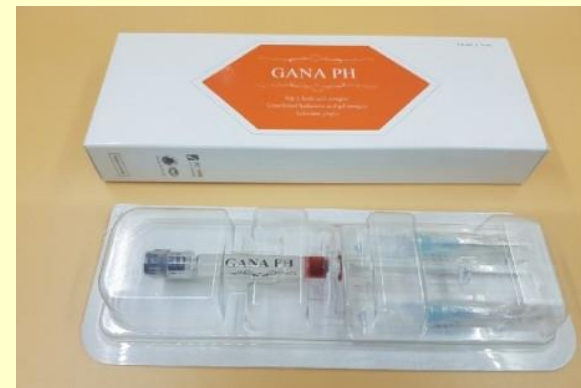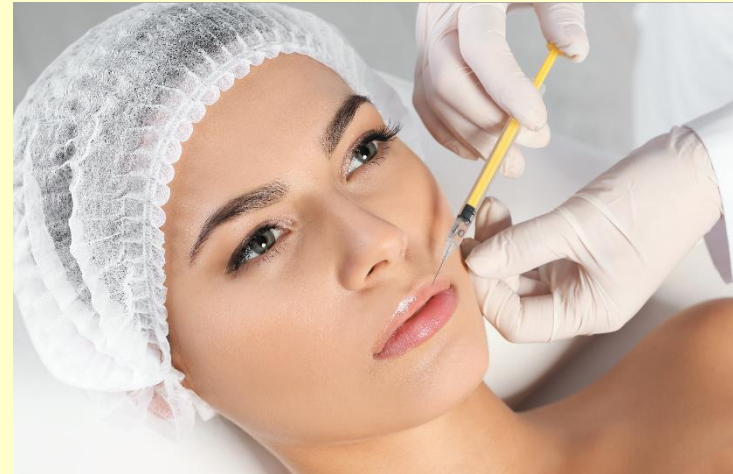- Botulinum toxin is a neurotoxic protein produced by the bacterium *Clostridium botulinum*.
- It prevents the release of the neurotransmitter acetylcholine from axon endings at the neuromuscular junction and thus causes flaccid paralysis.
- Infection with the bacterium causes the disease botulism.



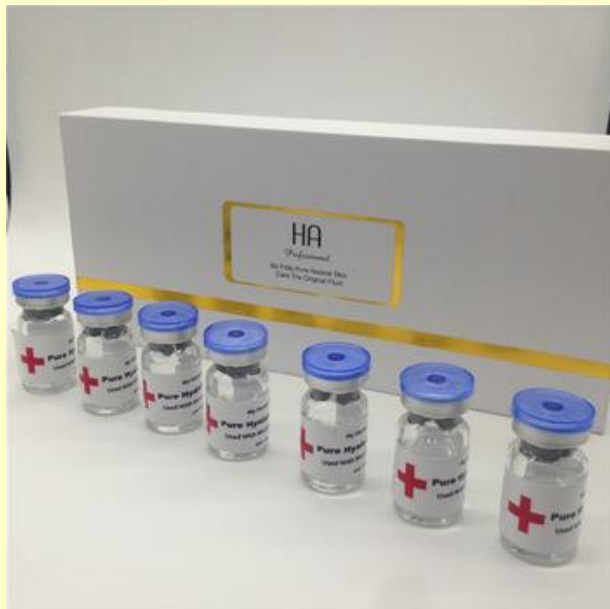

# Fillers المالتات

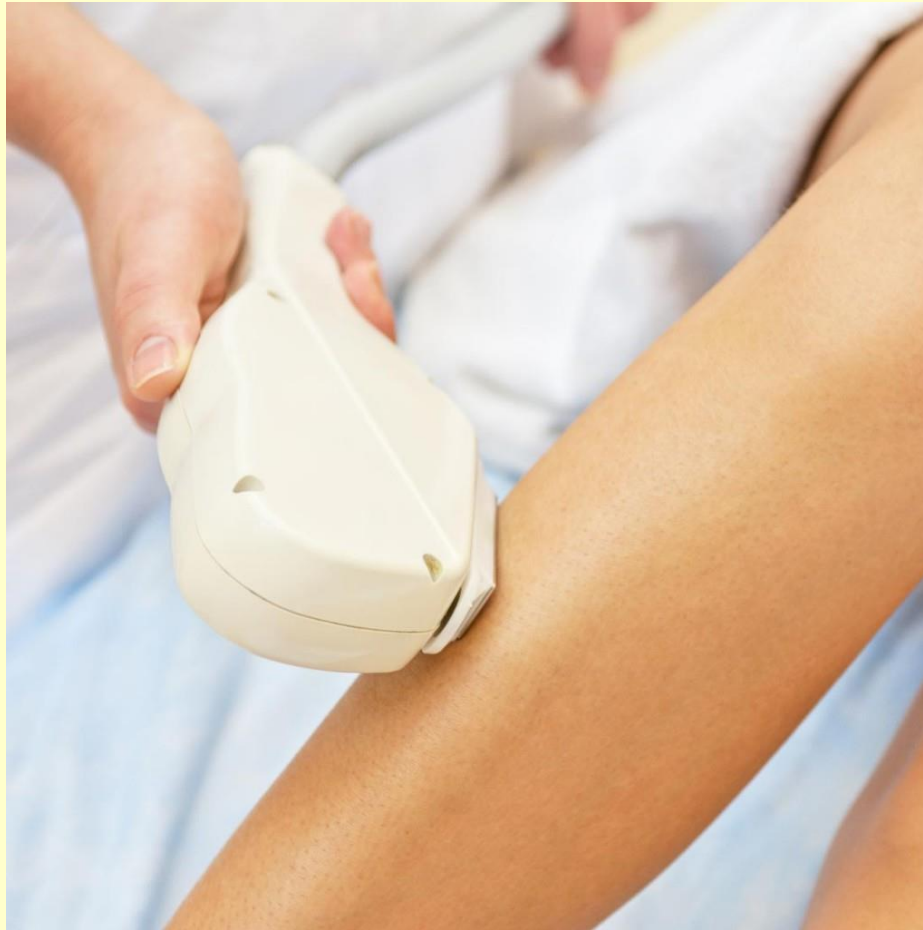- Dermal **fillers**: use hyaluronic acid and similar substances to "fill in" **or** plump areas that have lost volume and smoothness.
- 1 ml = ???



# Hyaluronic Acid injection



# Hair removal by Laser



# Thank You

