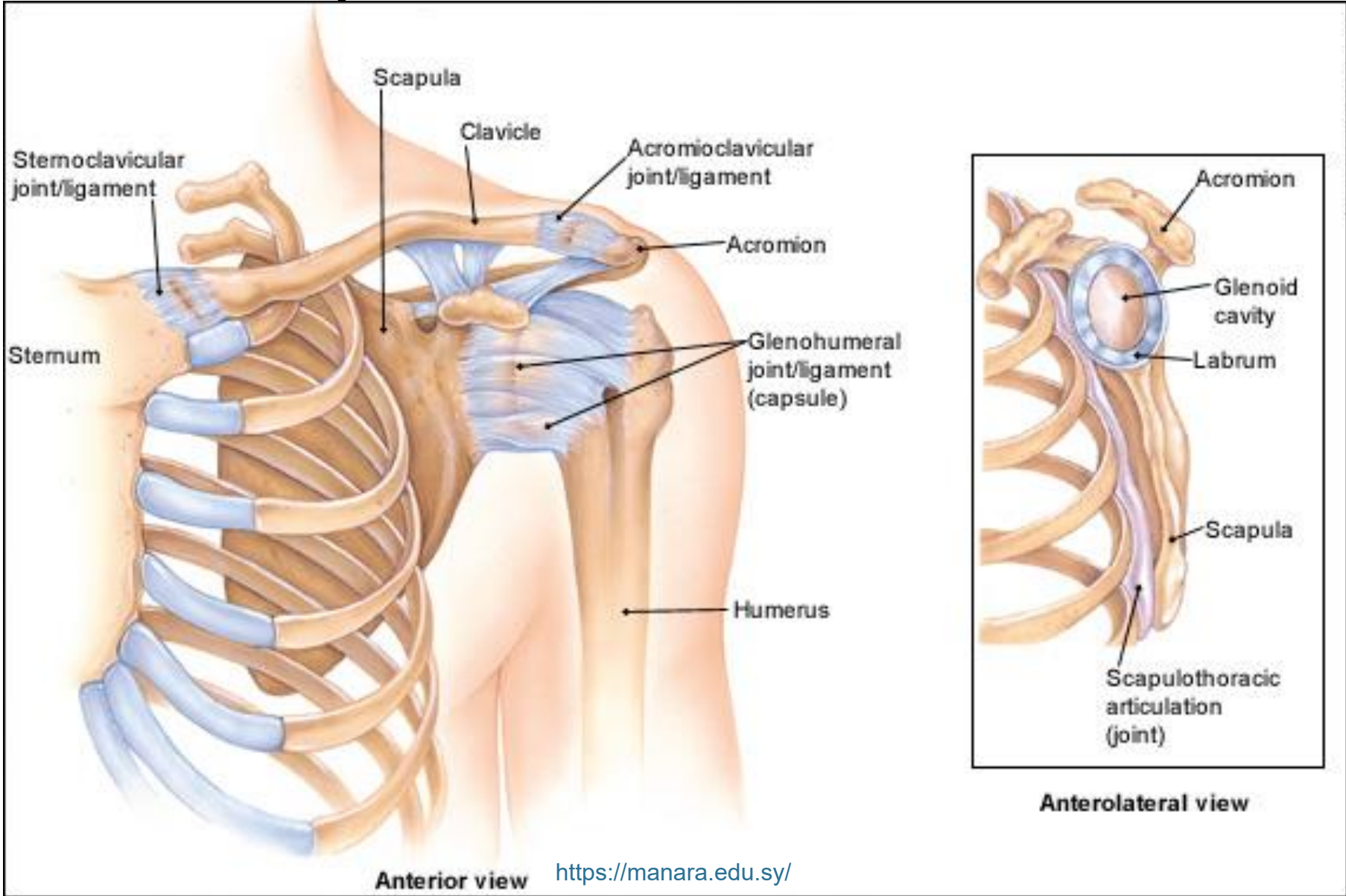
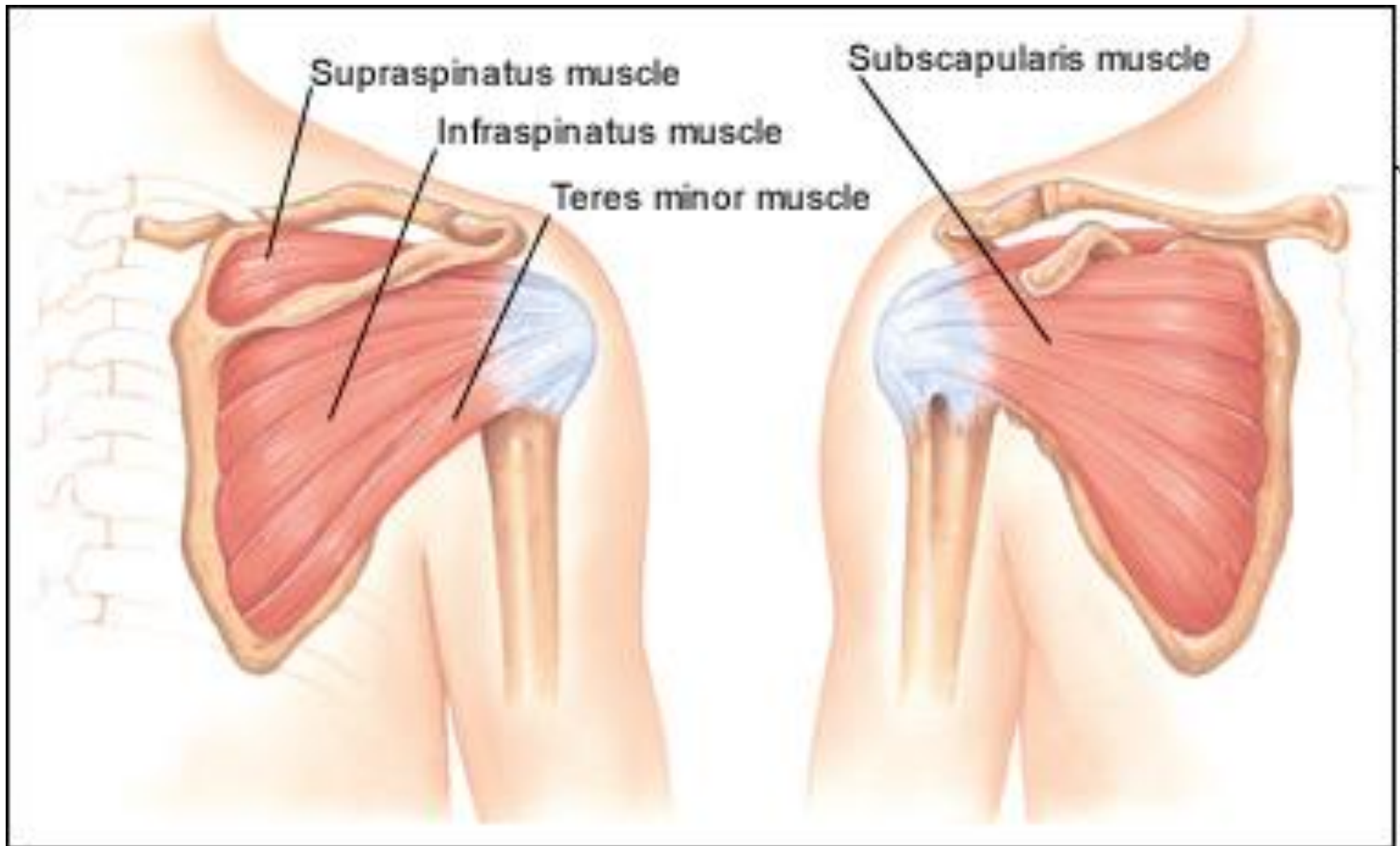


# Shoulder examination

# Anatomy





© 2000 Lydia Kibuk

# History

- Age
- work activity
- shoulder pain, instability, stiffness, locking, catching and swelling
- Stiffness or loss of motion
- Distinguishing between an acute and a chronic problem
- Once the location, quality, radiation, and aggravating and relieving factors

***FINDING******PROBABLE DIAGNOSIS***

Scapular winging, trauma, recent viral illness

Serratus anterior or trapezius dysfunction

Seizure and inability to passively or actively rotate affected arm externally

Posterior shoulder dislocation

Supraspinatus/infraspinatus wasting

Rotator cuff tear; suprascapular nerve entrapment

Pain radiating below elbow; decreased cervical range of motion

Cervical disc disease

## ***FINDING***

## ***PROBABLE DIAGNOSIS***

Shoulder pain in throwing athletes;  
anterior glenohumeral joint pain and  
impingement

Glenohumeral joint instability

Pain or “clunking” sound with  
overhead motion

Labral disorder

Nighttime shoulder pain

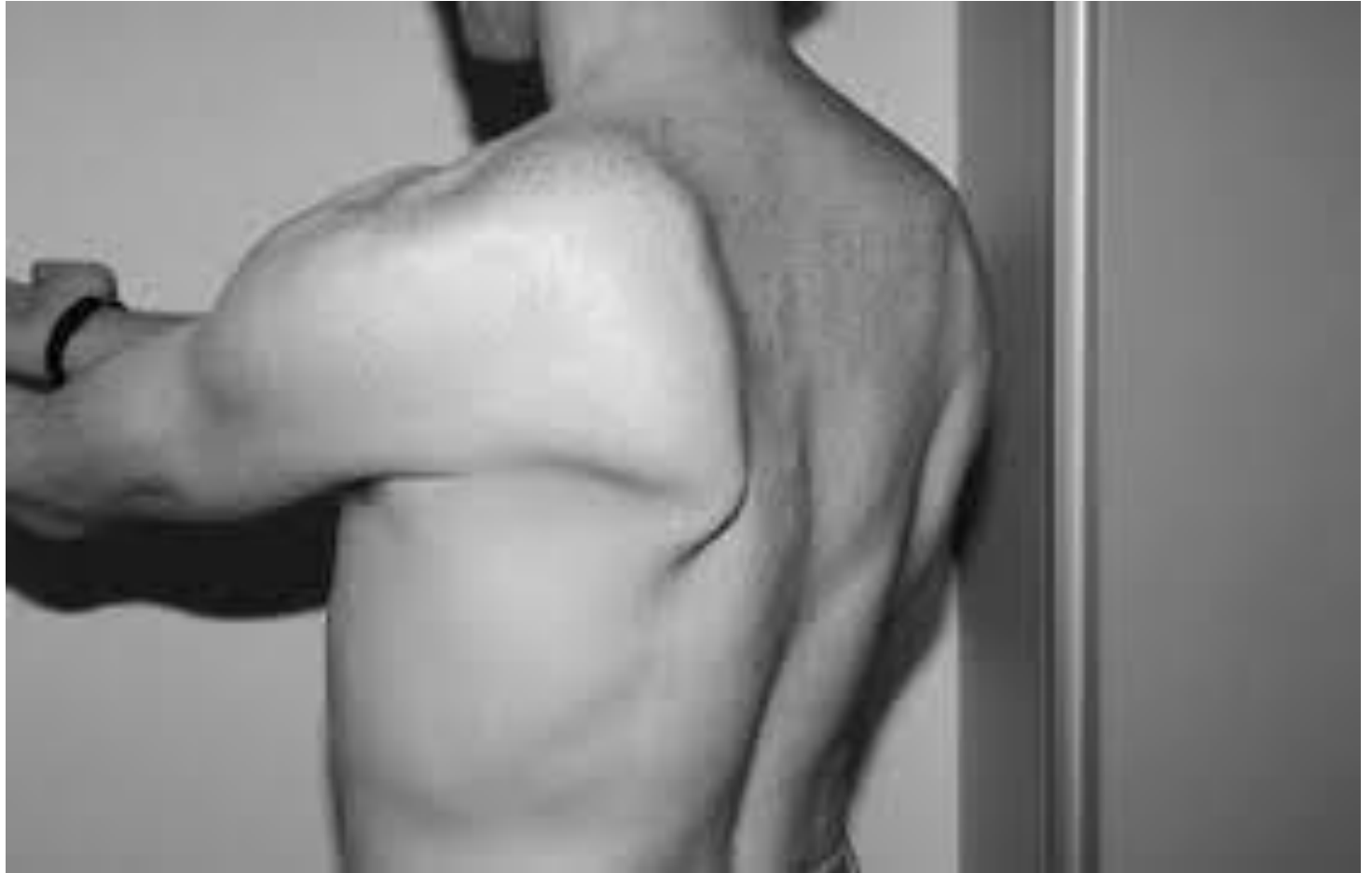Impingement

Generalized ligamentous laxity

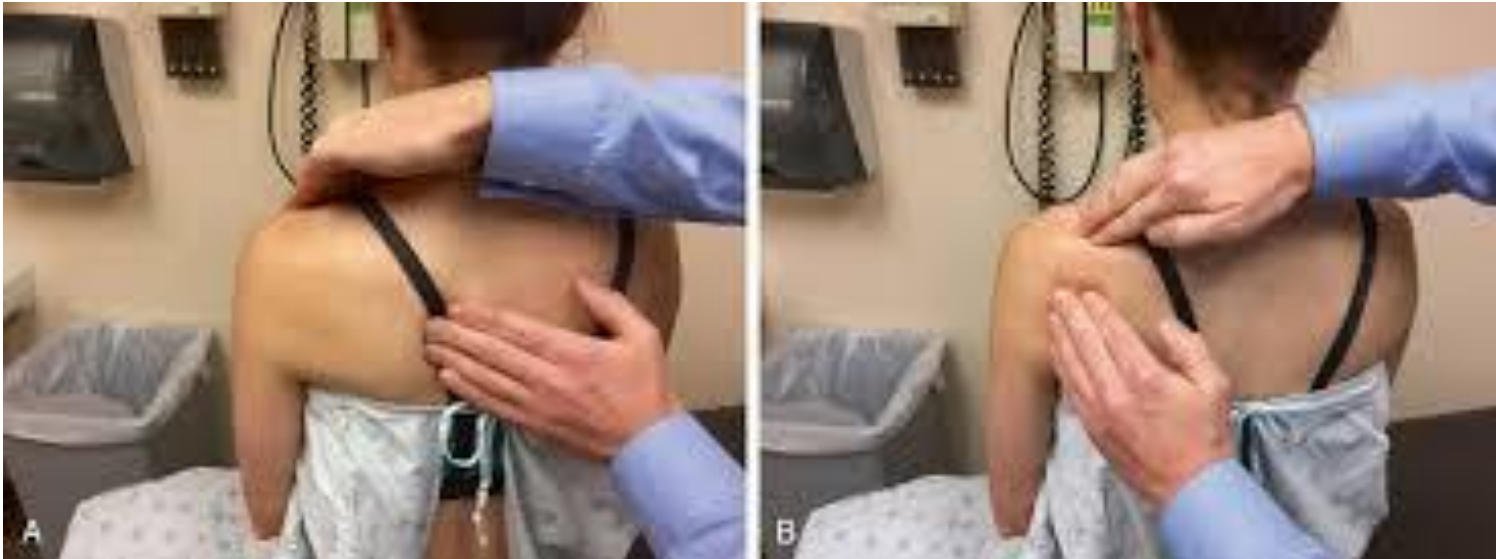Multidirectional instability

# Physical Examination

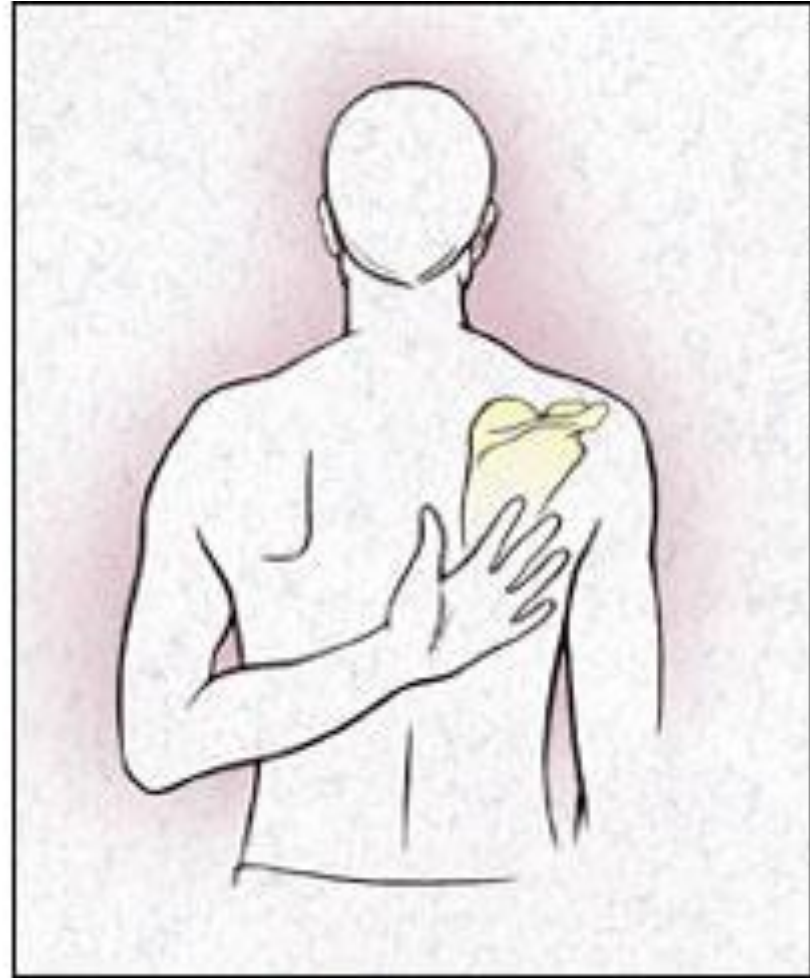
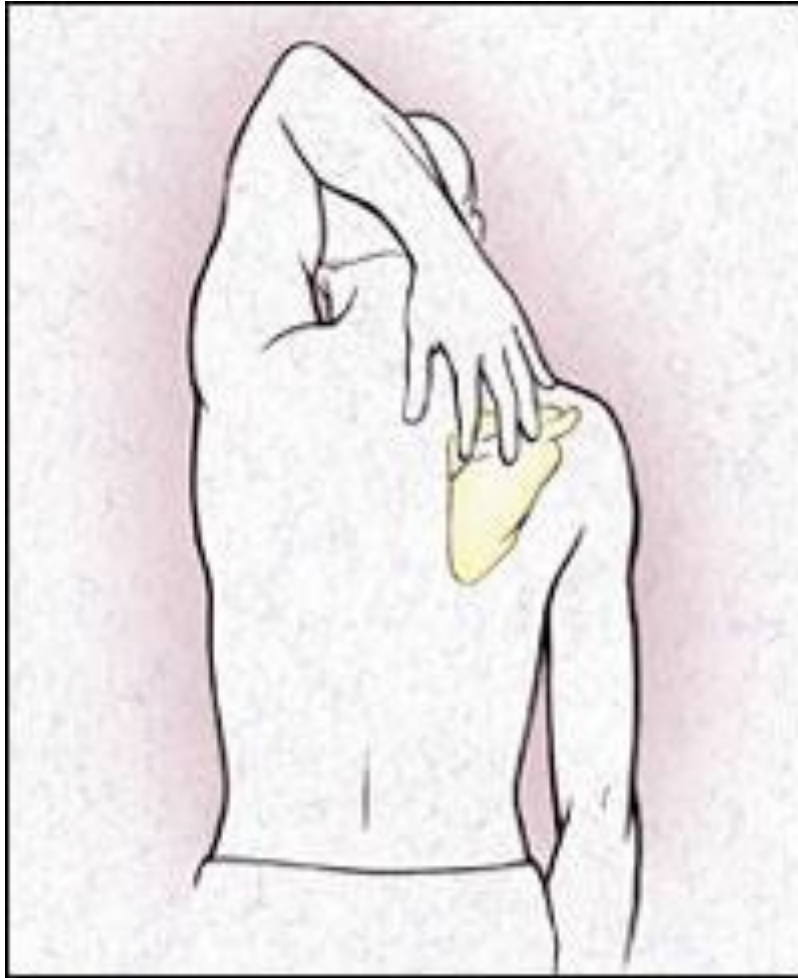- **INSPECTION** Swelling, asymmetry, muscle atrophy, scars, ecchymosis and Deformity.
- **PALPATION:** Pain and heat
- **RANGE-OF-MOTION TESTING**







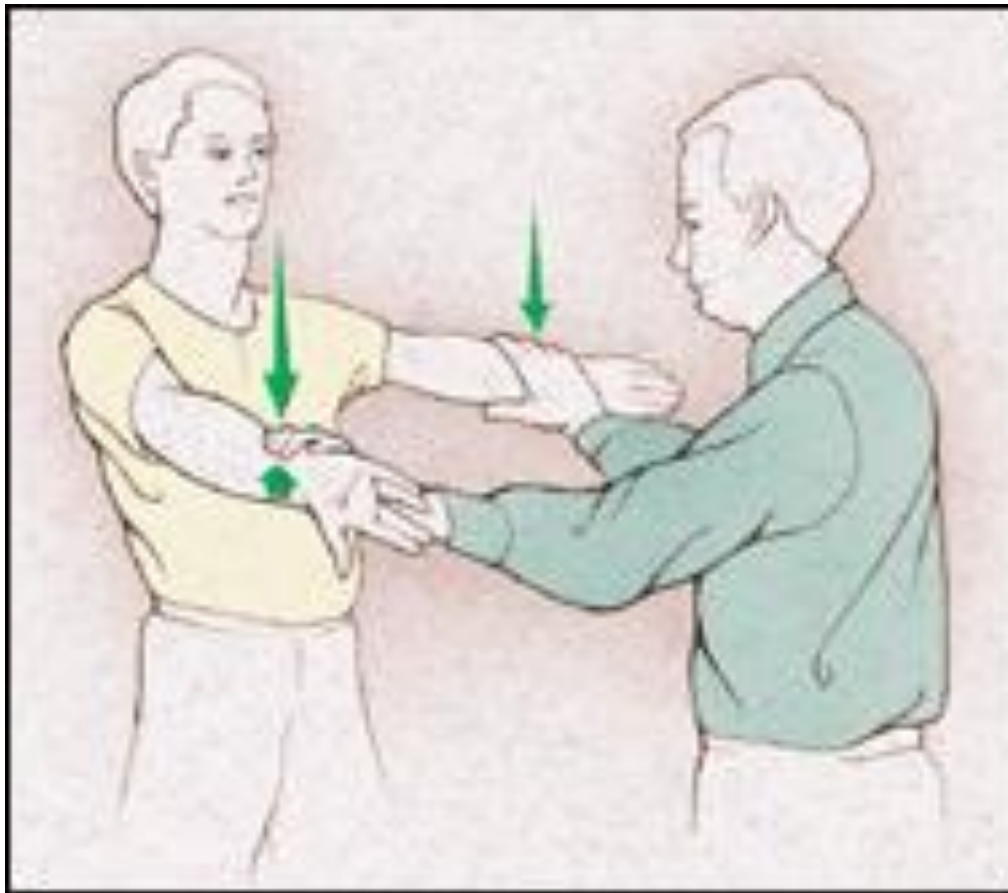
# Apley scratch test



© 2000 Marcia Harstock

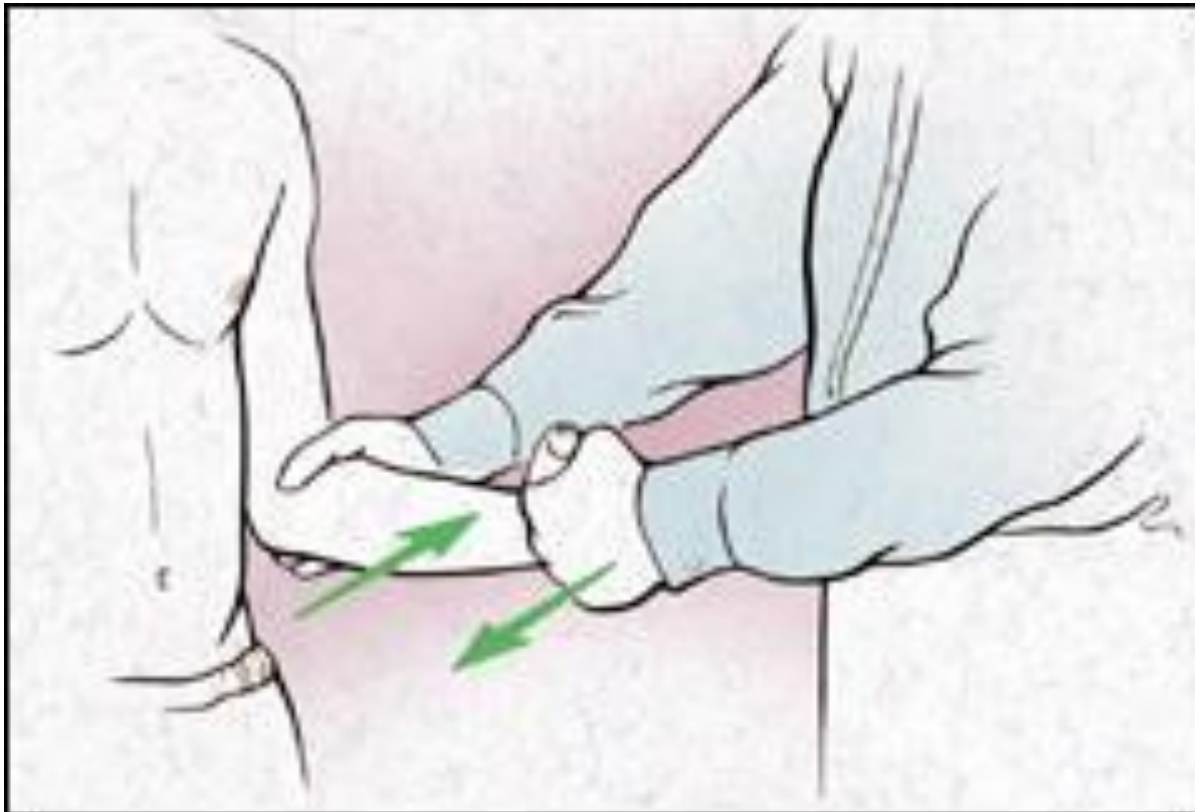# EVALUATING THE ROTATOR CUFF

- supraspinatus



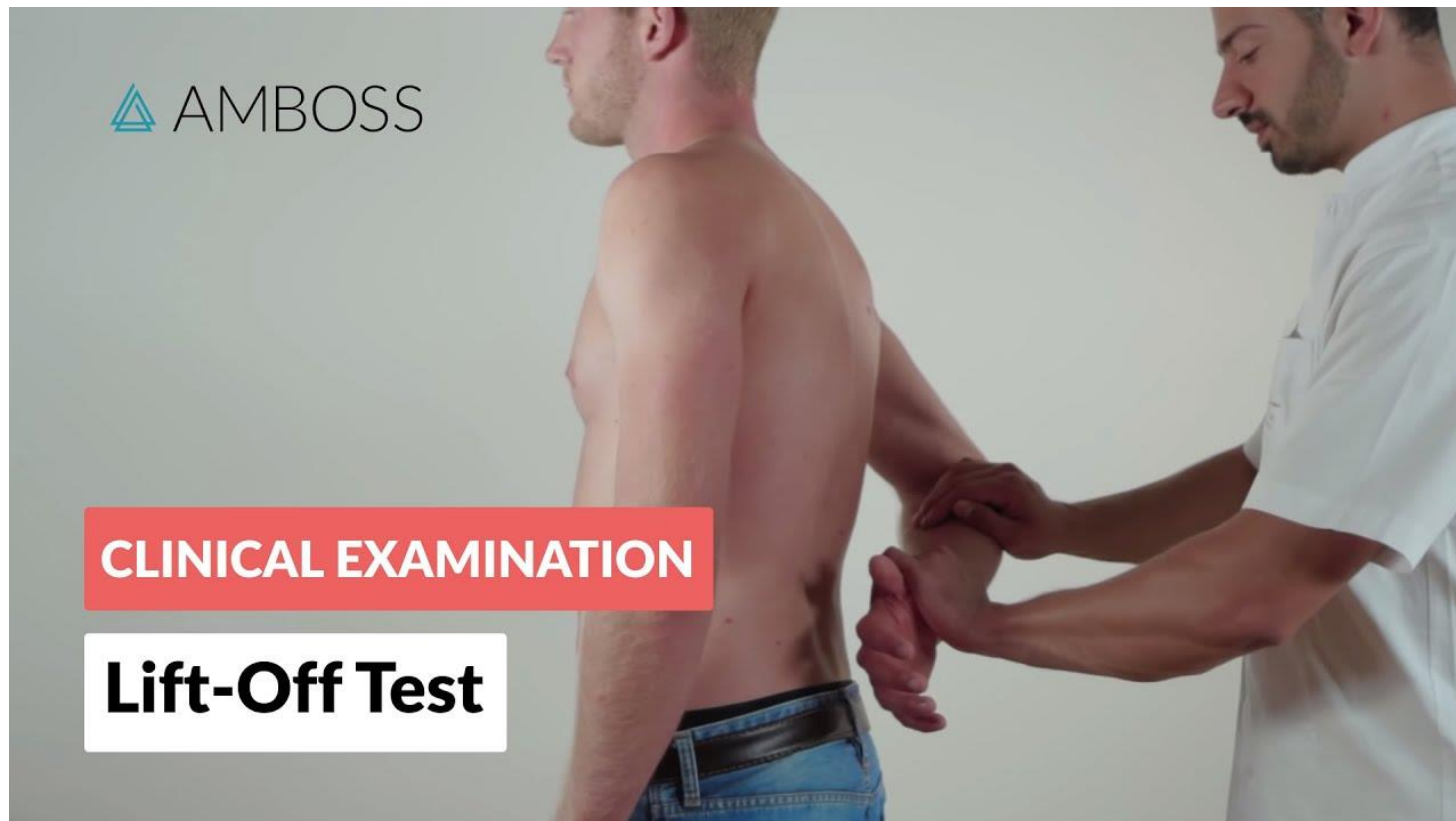
© 2000 Marcia Harstock

- infraspinatus and teres minor muscles for external rotation.

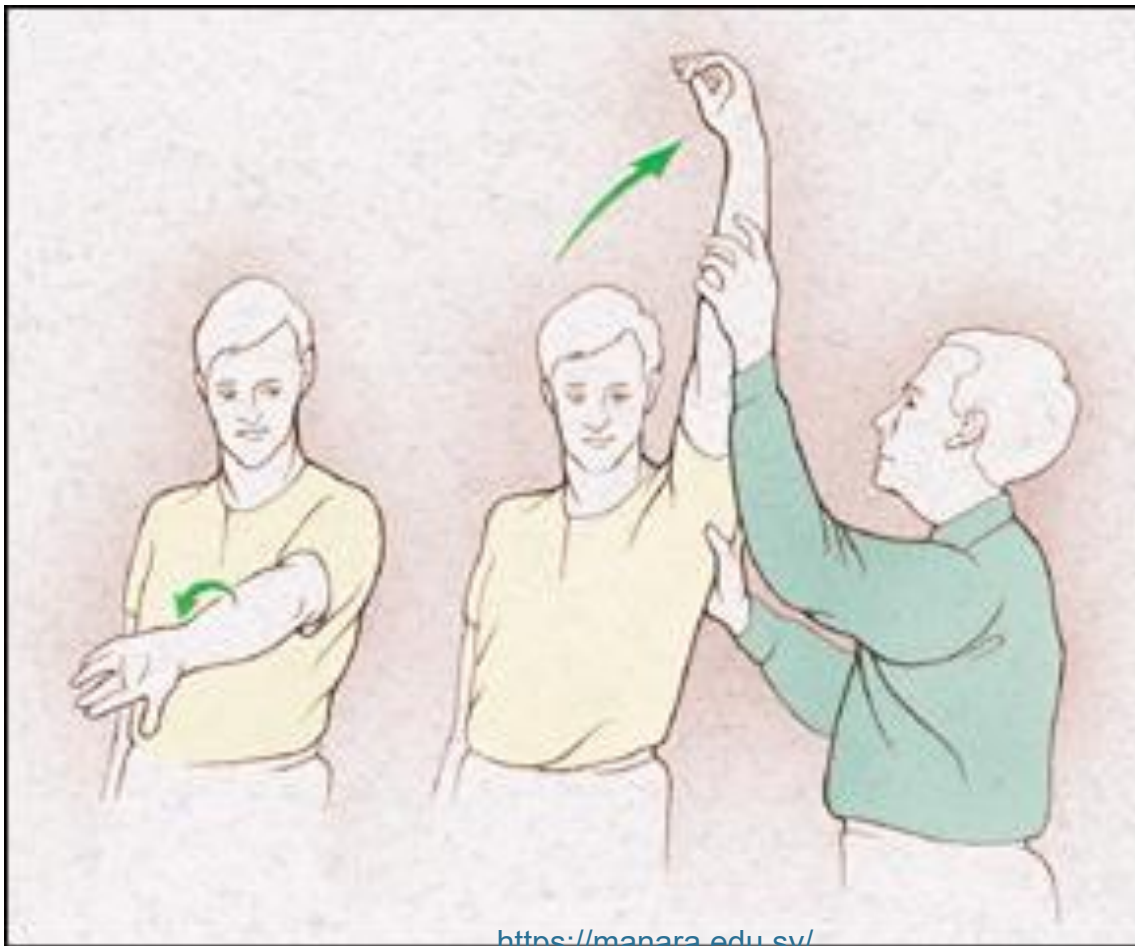


© 2000 Marcia Harstock

- Subscapularis for internal rotation



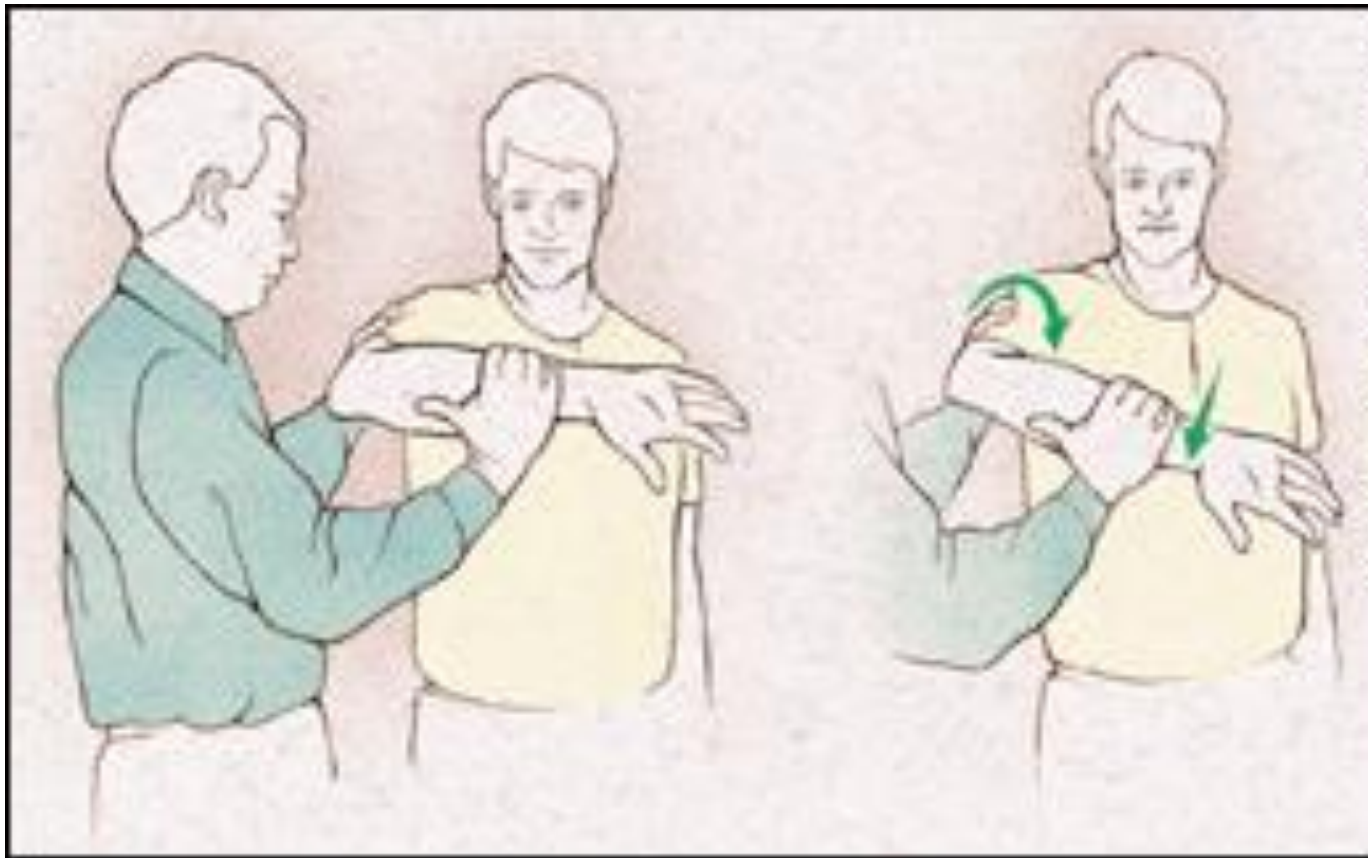
- NEER'S TEST



© 2000 Marcia Harstock



- HAWKINS' TEST



© 2000 Marcia Harstock