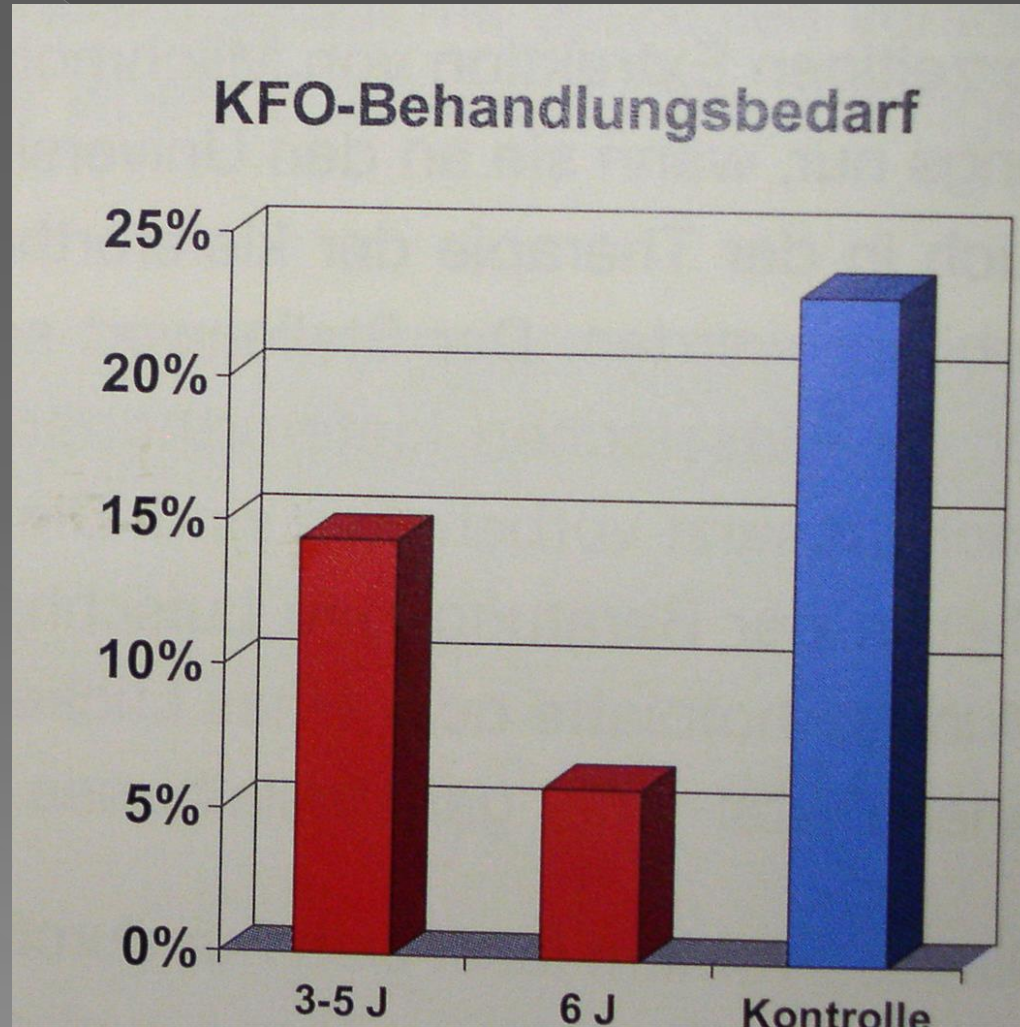


Early orthodontic interventions & Space Regaining

Dr. Abdul Wahab Nourallah

Why early ortho. intervention?



- ◉ Protect your child's jaw development
- ◉ Best start / self confidence
- ◉ Straight teeth allow for a cleaner mouth

Decision making

Early orthod. VS Late orthod.

?

"An Ounce of Prevention is Worth a Pound of Cure"

Early treatments with proven benefits

- ◉ Anterior and posterior cross-bites, (specially Cross-bites associated with mandibular shifts)
- ◉ Excessive protrusions and diastemas
- ◉ Severe anterior or lateral open bites
- ◉ Space regaining
- ◉ Clift lip and palate
- ◉ Bad oral habits

Crossbites

**“The best time to treat a crossbite is
as early as you can”**

DEVELOPING ANTERIOR CROSSBITE:

- Anterior cross bite is a condition characterized by reverse overjet wherein one or more maxillary anterior teeth are in lingual relation to the mandibular teeth.
- Should be intercepted and treated at an early stage to prevent a **minor orthodontic problem** from progressing into **a major dento-facial anomaly**.
- Or else it may grow into **skeletal malocclusion**

Anterior Crossbites Classification:

- Dento-alveolar anterior crossbite.
- Skeletal anterior crossbite.
- Functional anterior crossbite.

Dento-alveolar anterior crossbite:

- One or more maxillary anterior teeth are in lingual relation to the mandibular anteriors.
- Treated using tongue blades , double cantilever springs.

Functional anterior crossbite:

- Pseudo class III malocclusion.., where the mandible is compelled to close in a position forward of it's true centric relation.
- Treated by eliminating occlusal prematurities.

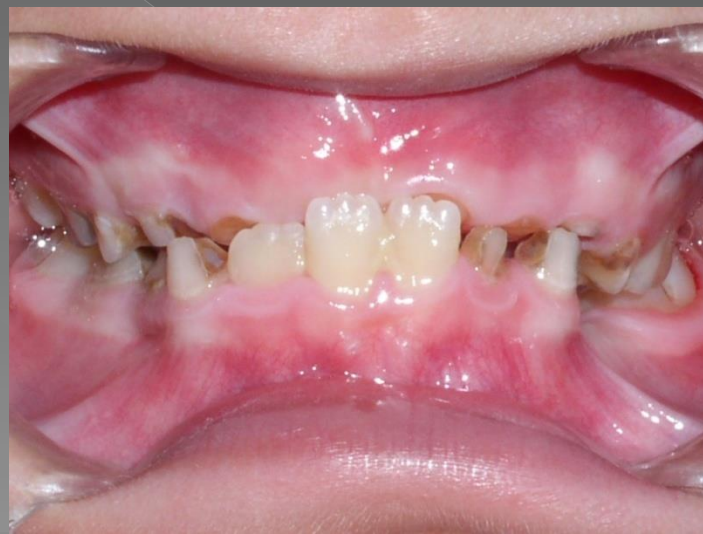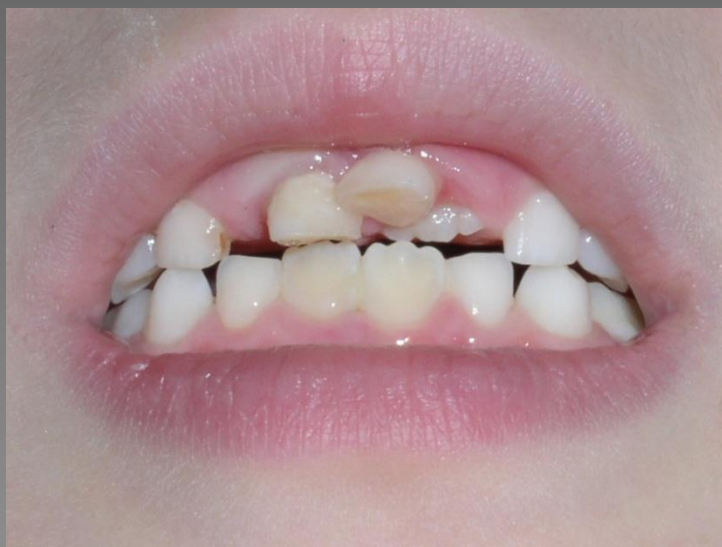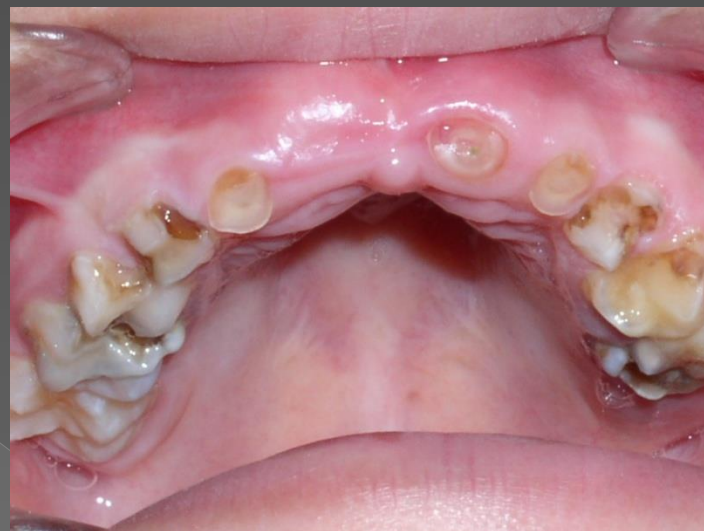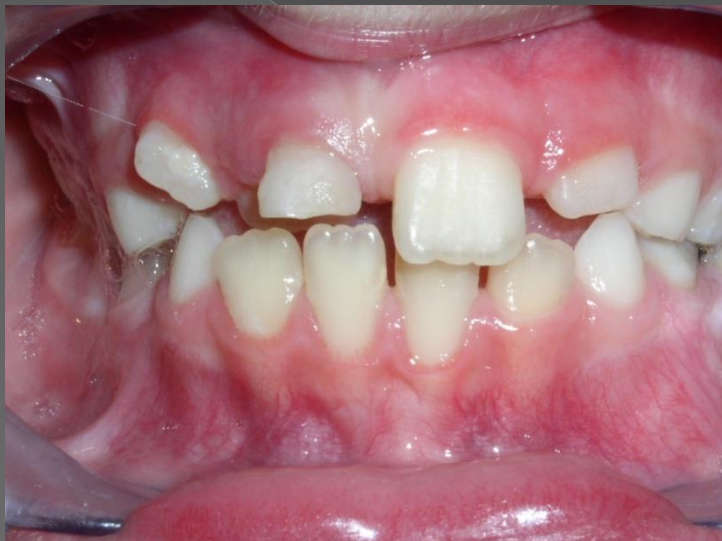Skeletal anterior cross-bite:

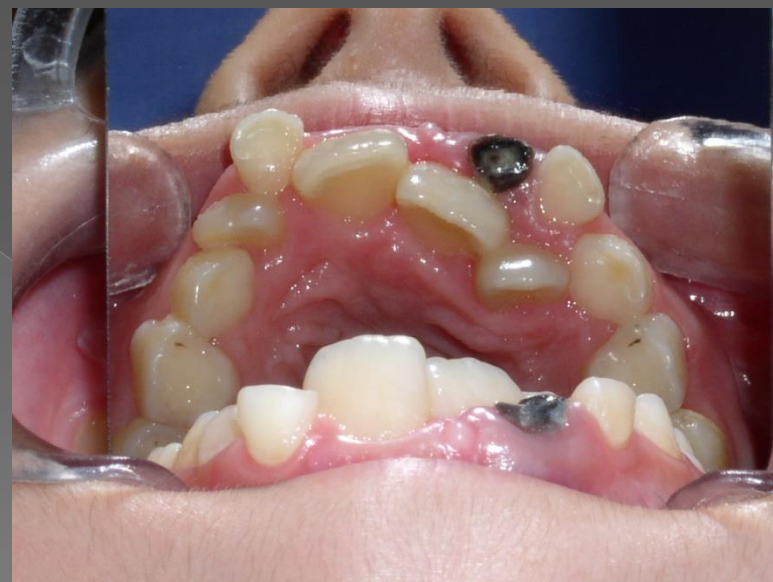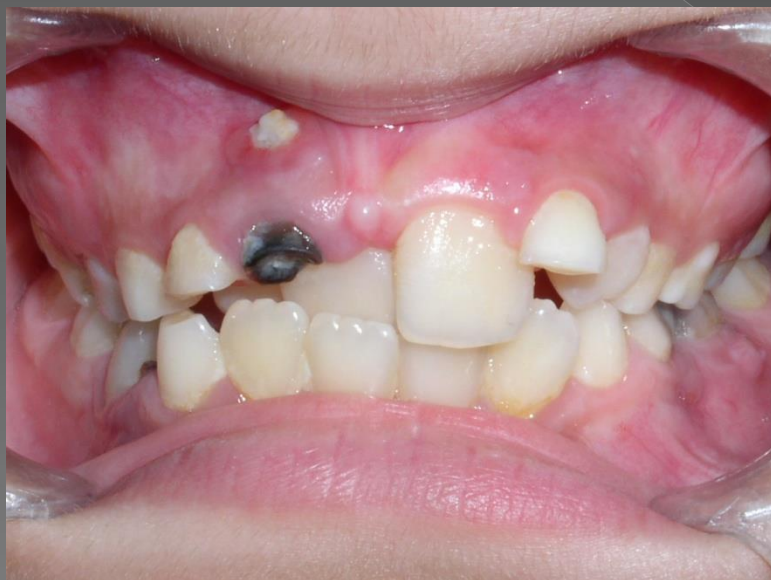- Treated by myofunctional or orthopaedic appliances

Causes of anterior crossbite

- Prolonged retention of primary teeth/tooth
- Space deficiency (caries, early loss, ectopic eruption,...)
- Arch tooth-size discrepancy
- Premature contacts
- Supernumerary teeth
- Skeletal

Causes of anterior crossbite

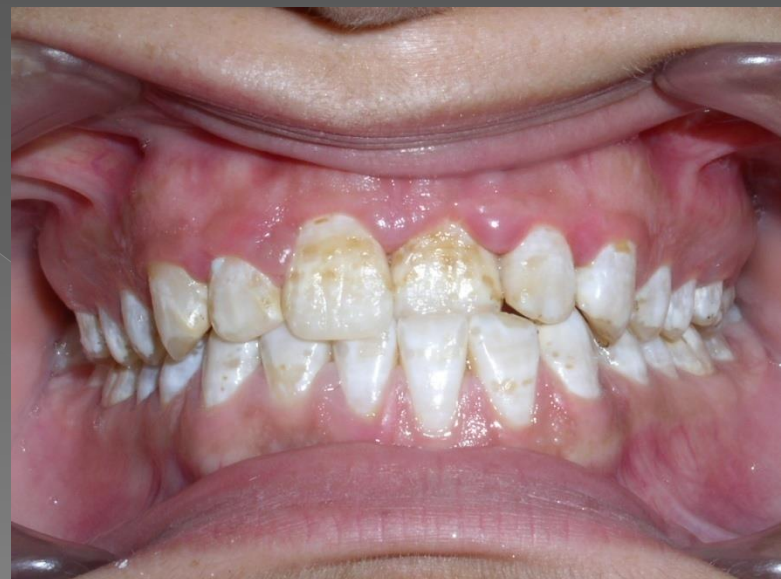
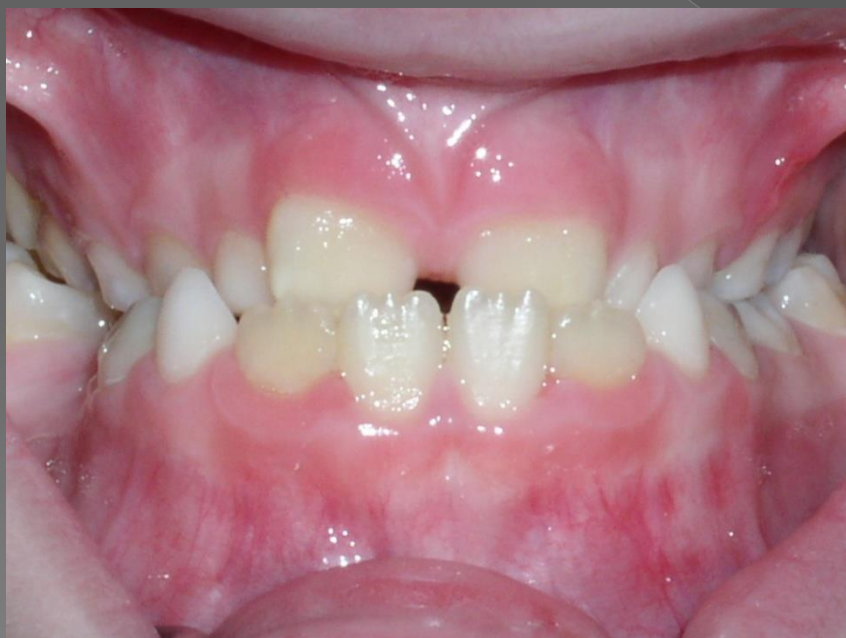


Diagnosis

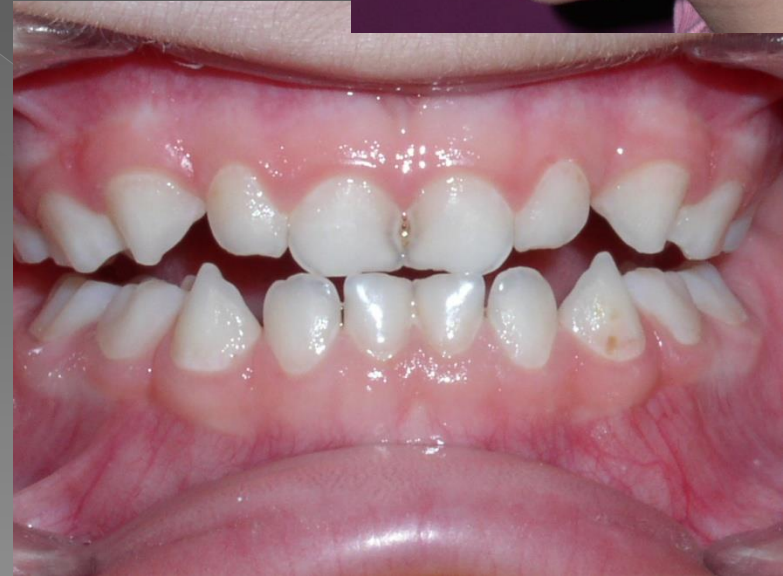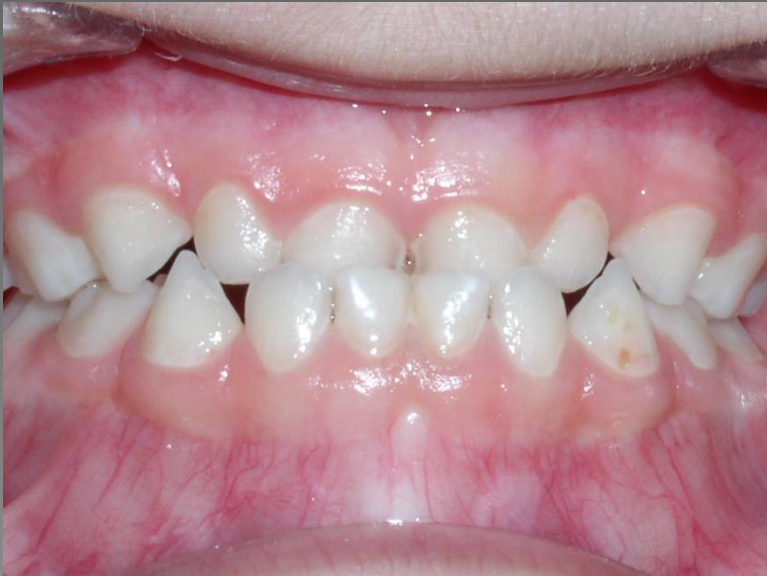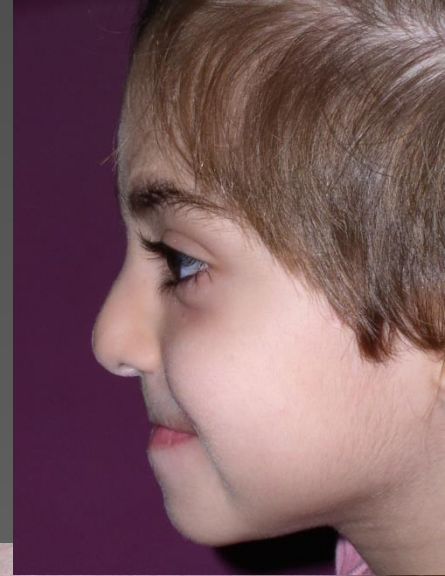- القصة المرضية
- العلامات داخل و خارج الفموية
- الفحص الوظيفي
- فحص و دراسة الأمثلة الجبسية
- التصوير الشعاعي - سيفالومتري

تشخيص العضة المعكوسة

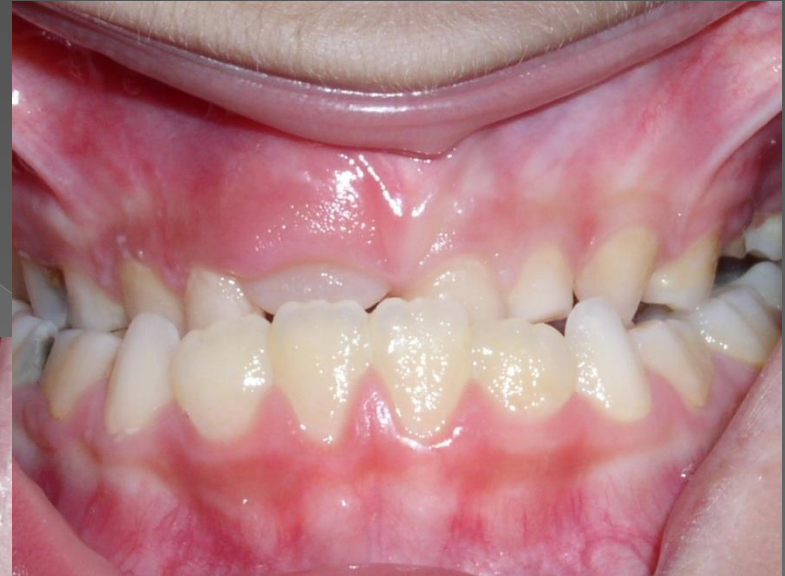
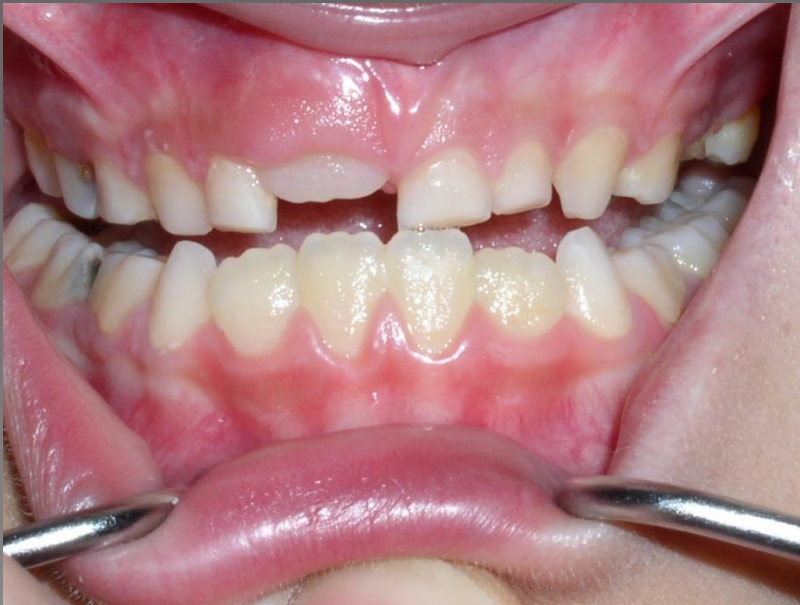
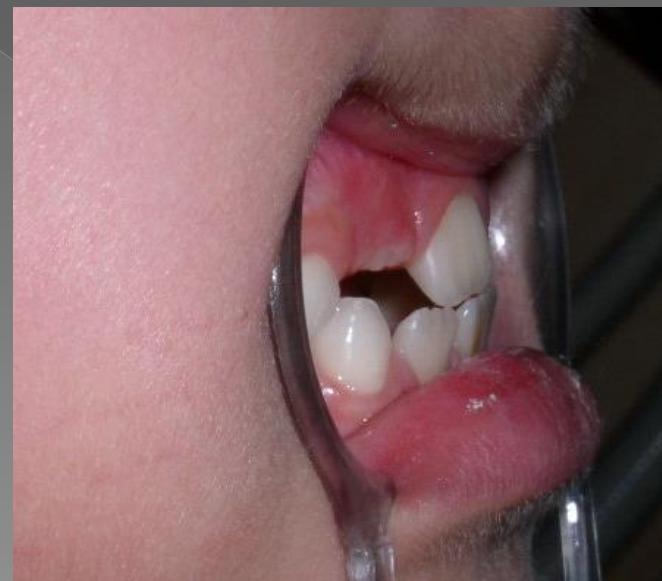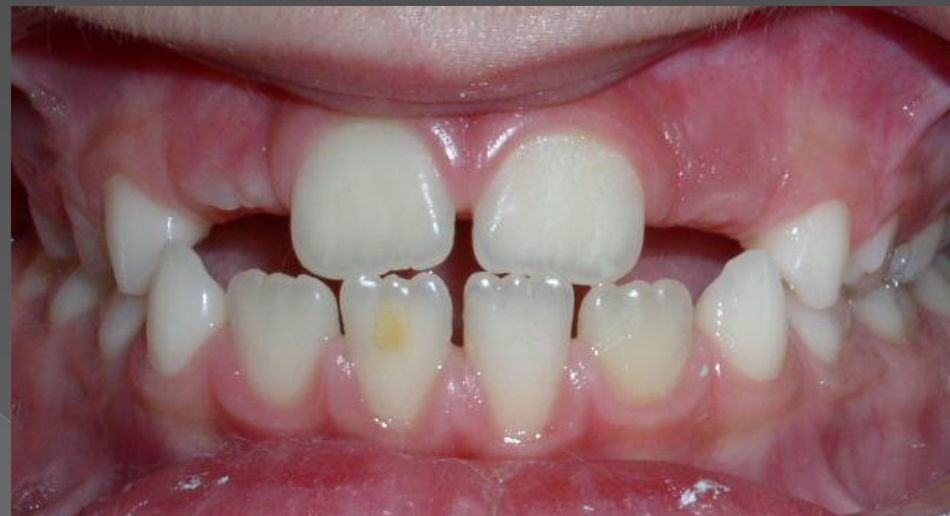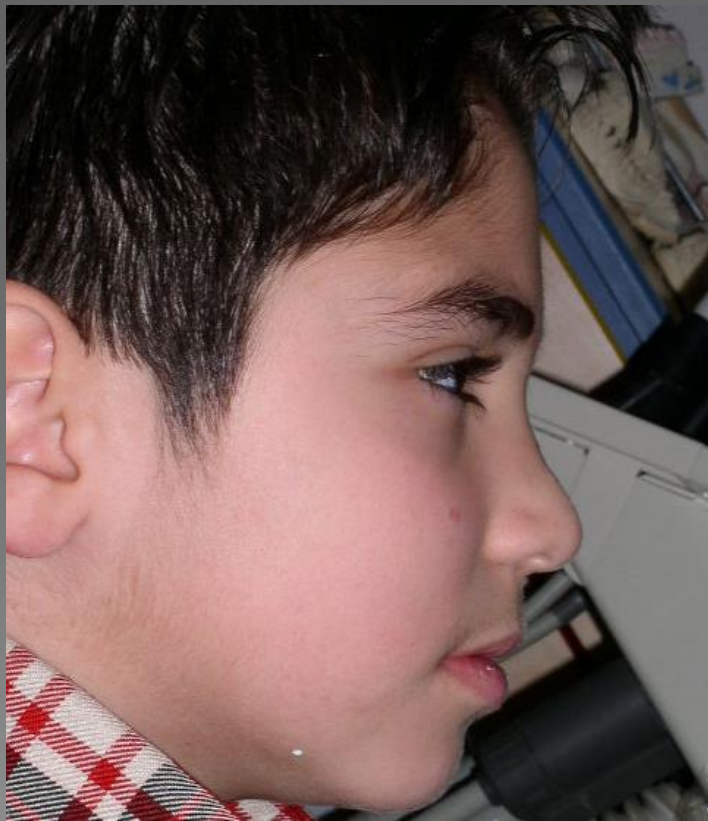تشخيص العضة المعكوسة

Functional inspection

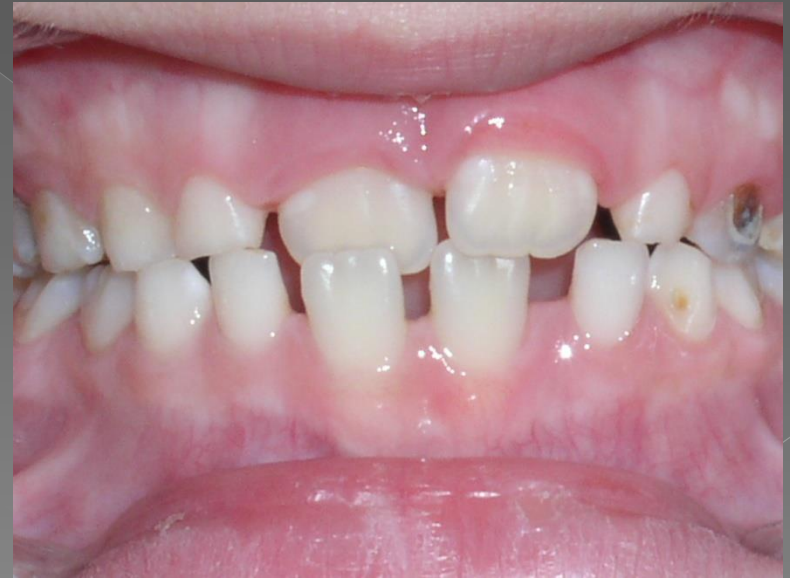
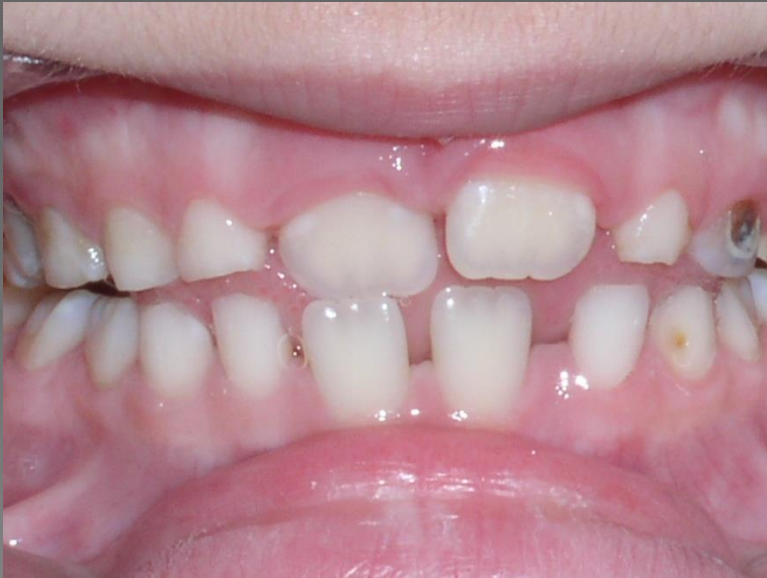
تشخيص العضة المعكوسة

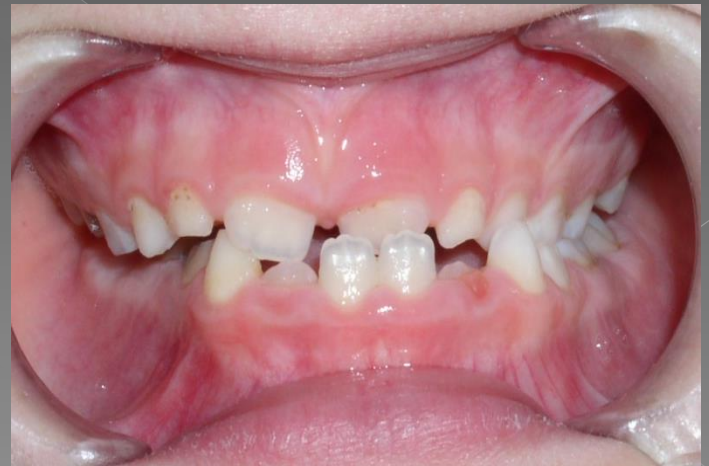
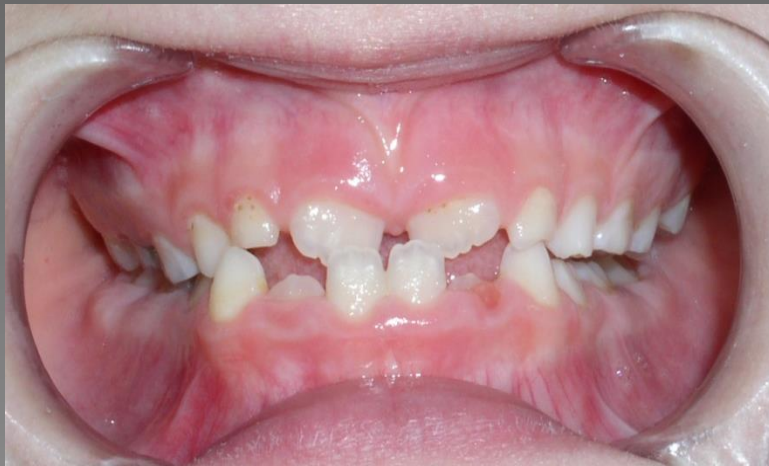
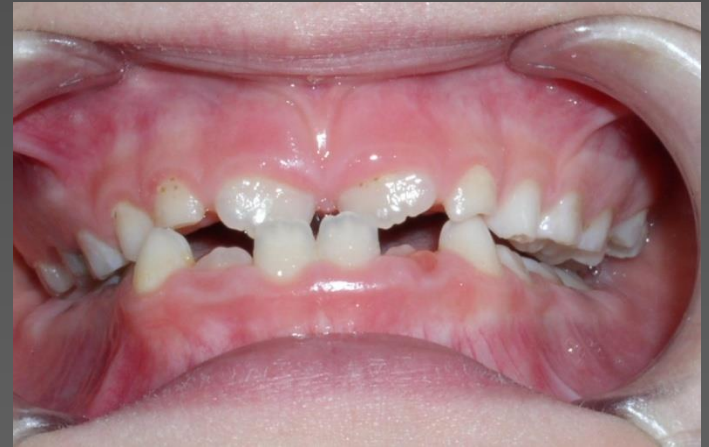
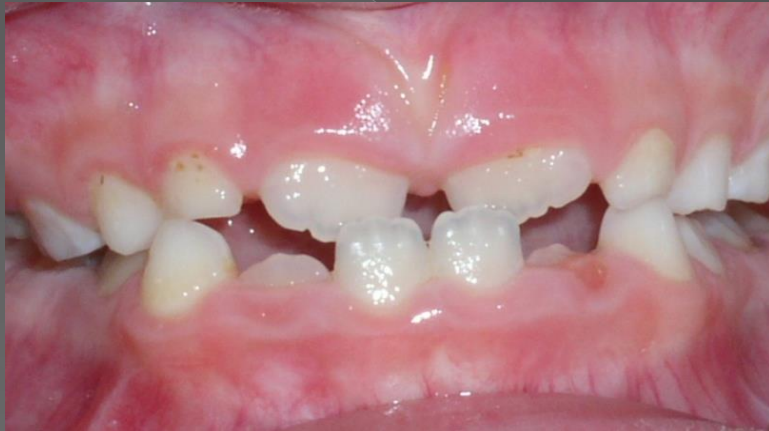
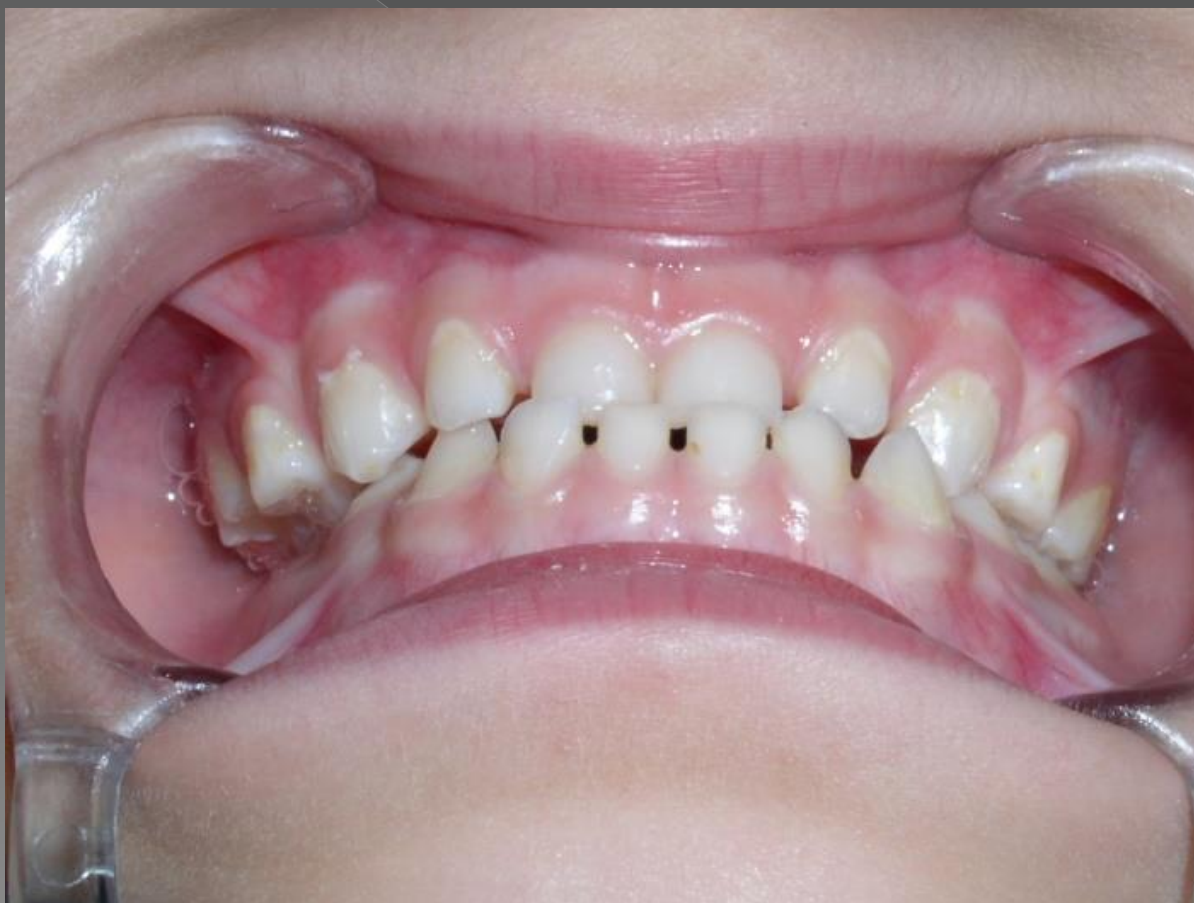Functional inspection



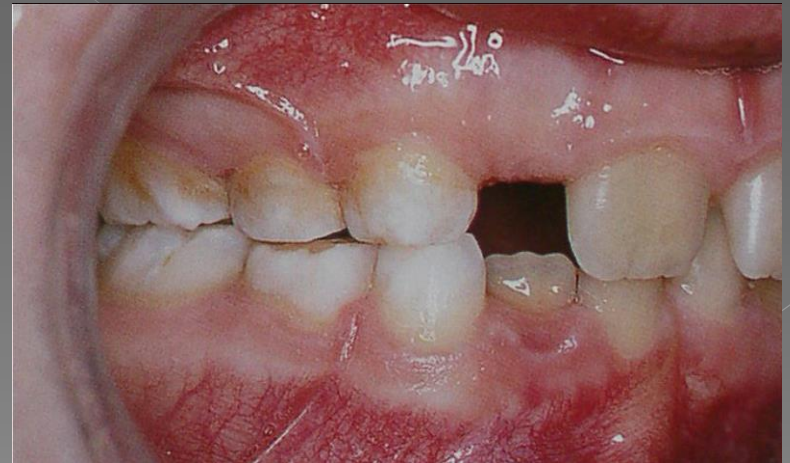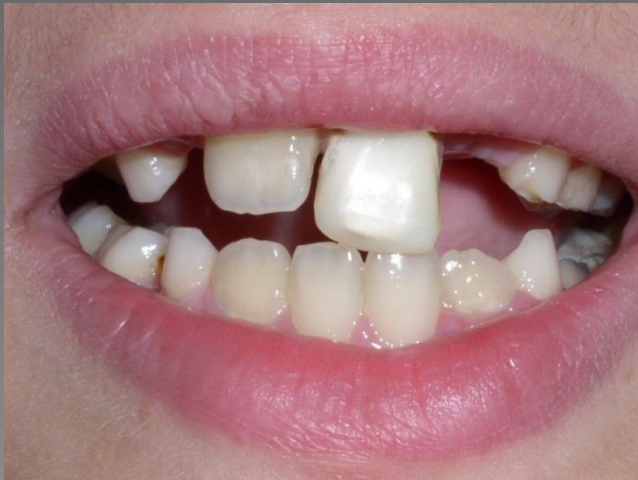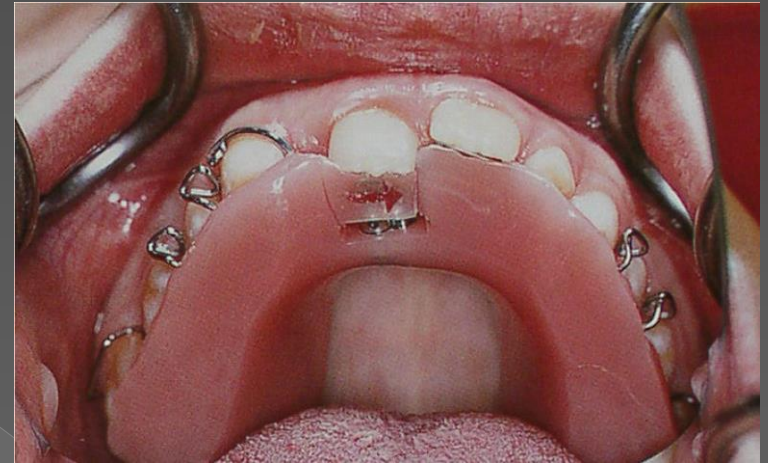
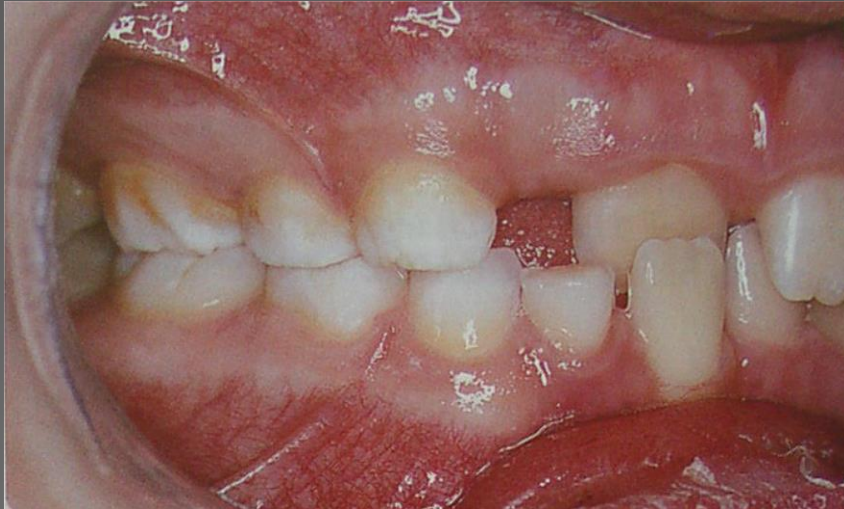Compound cases



Compound cases

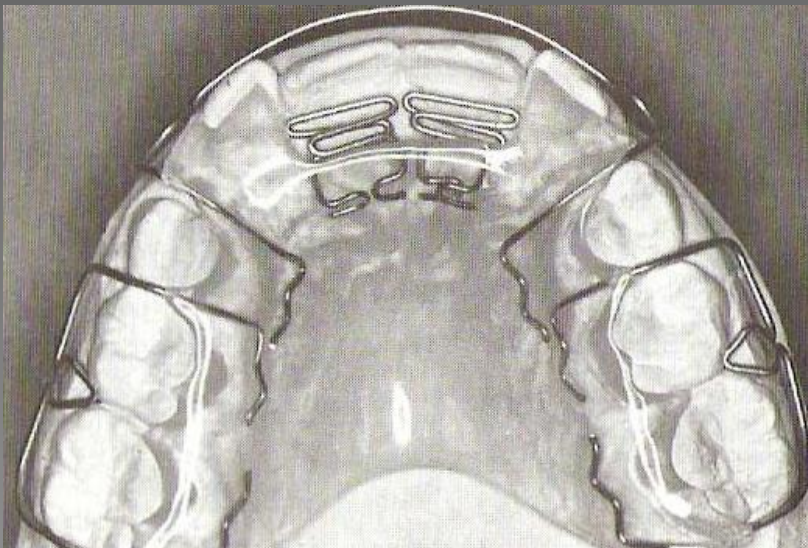
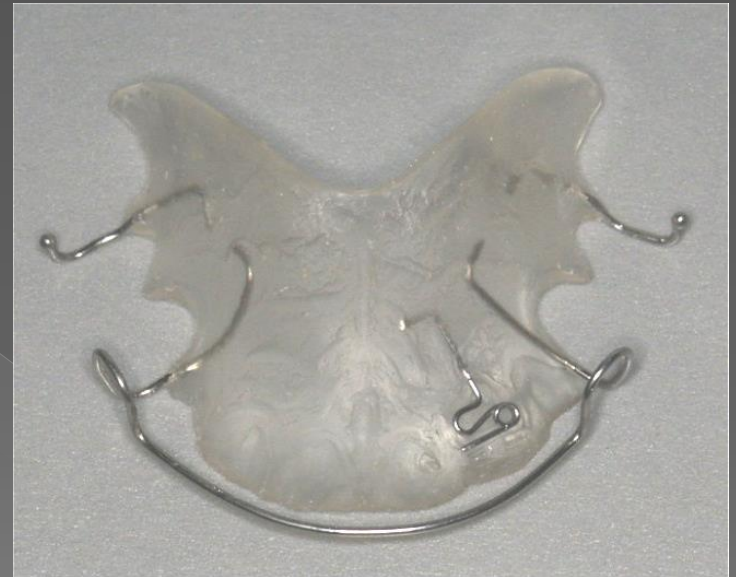

Anterior Crossbite treatment choices

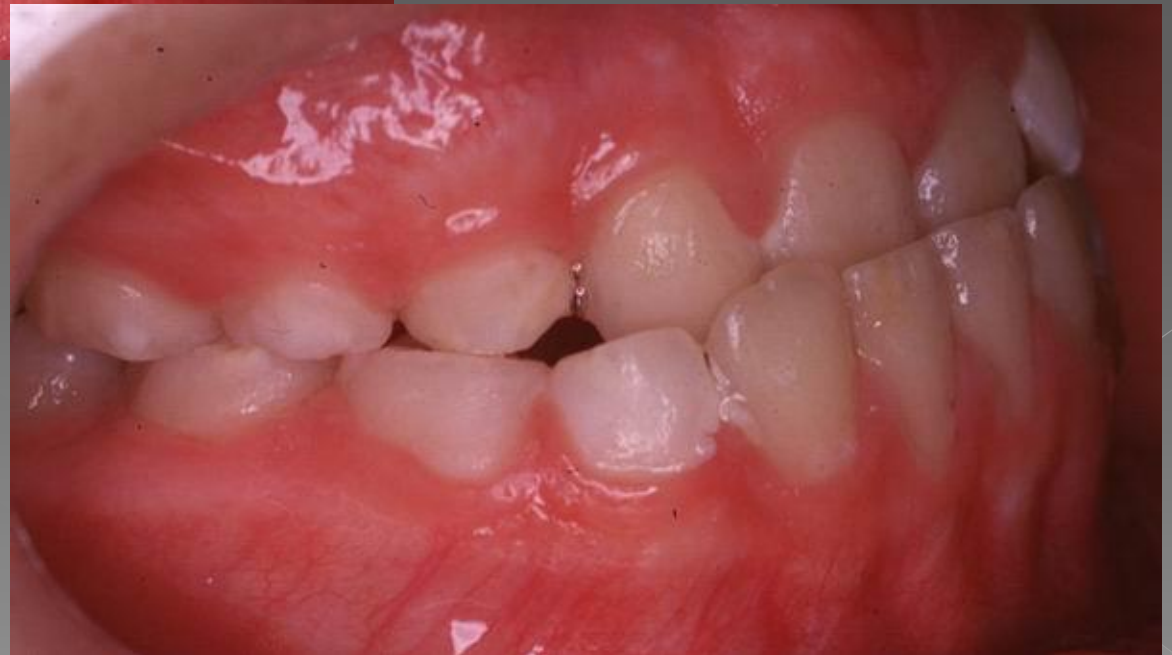
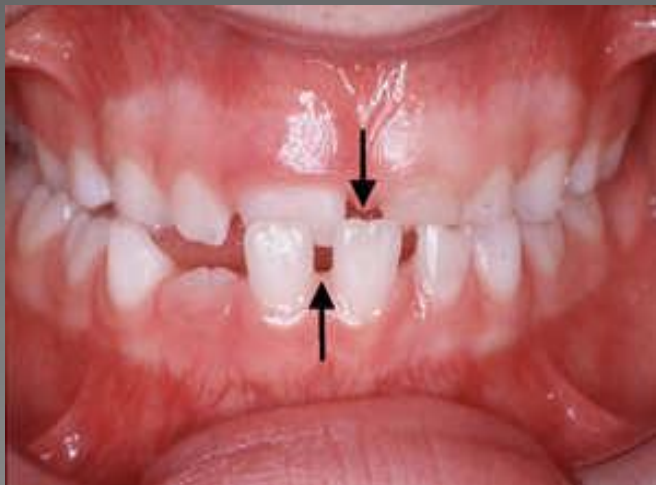
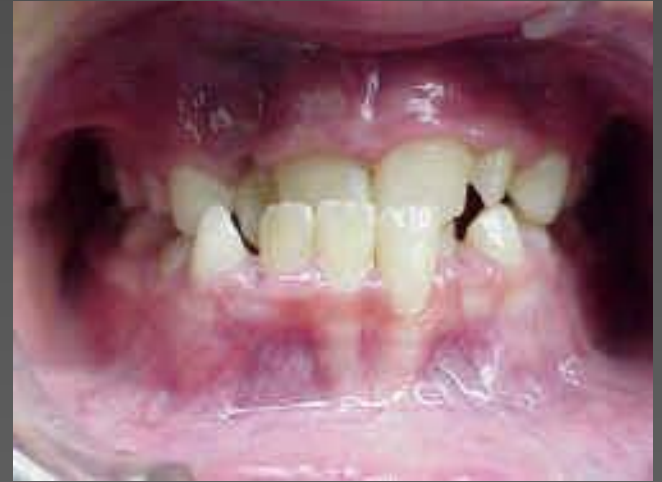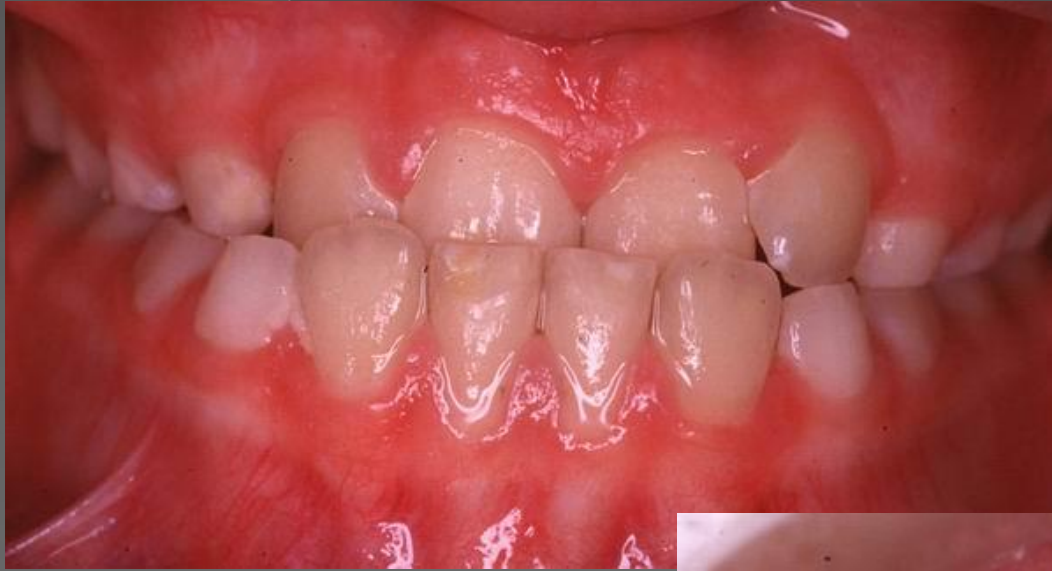Simple appliances

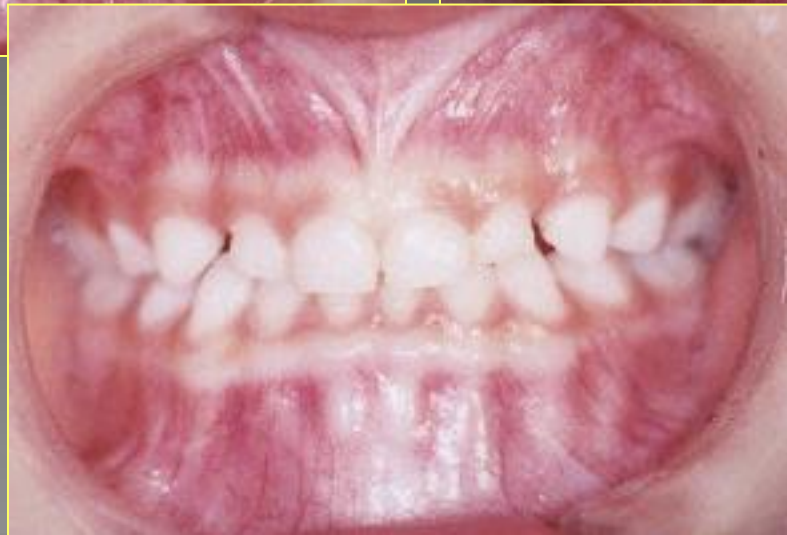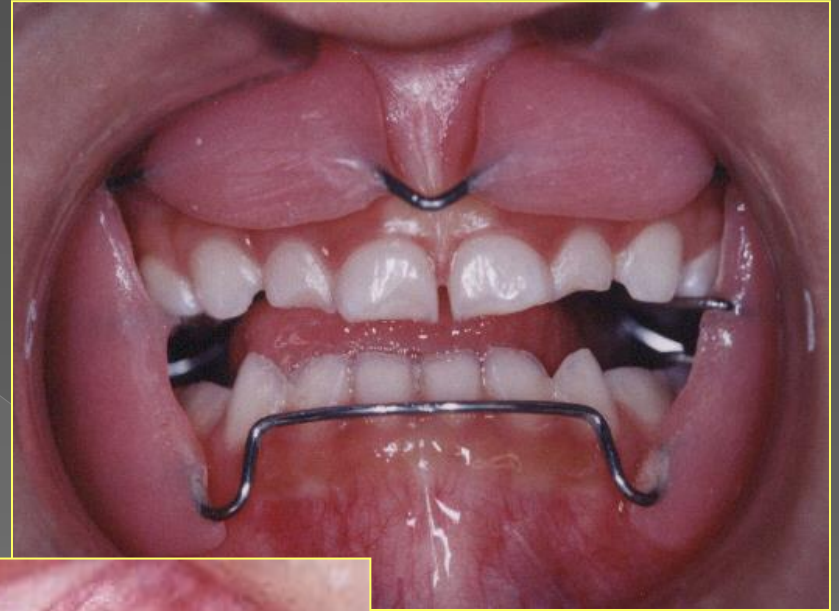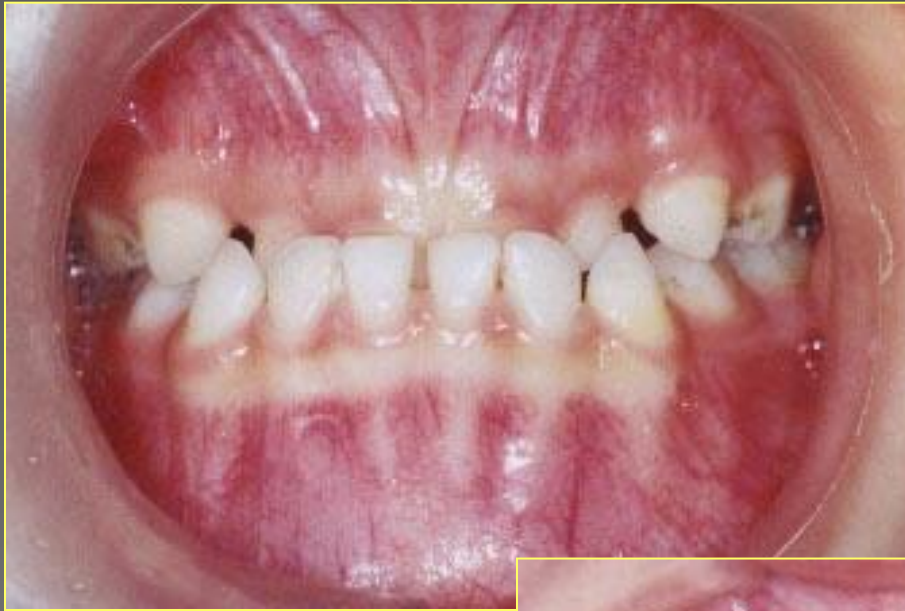- Biteblock
- Right force



Skeletal Anterior Crossbite



Functional appliances for skeletal crossbites

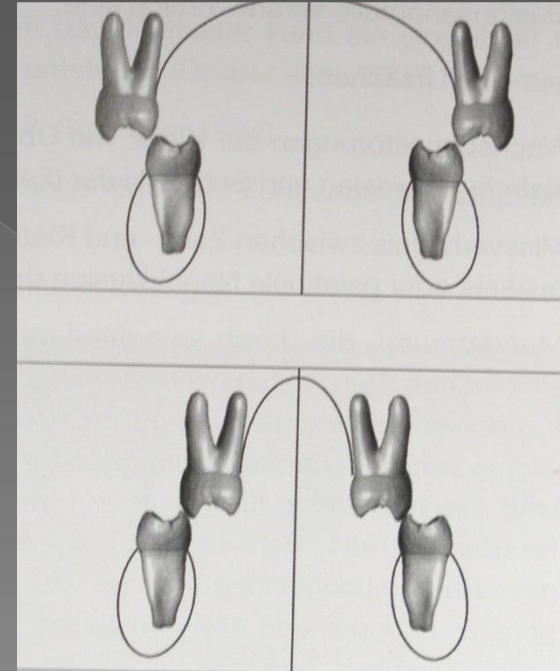
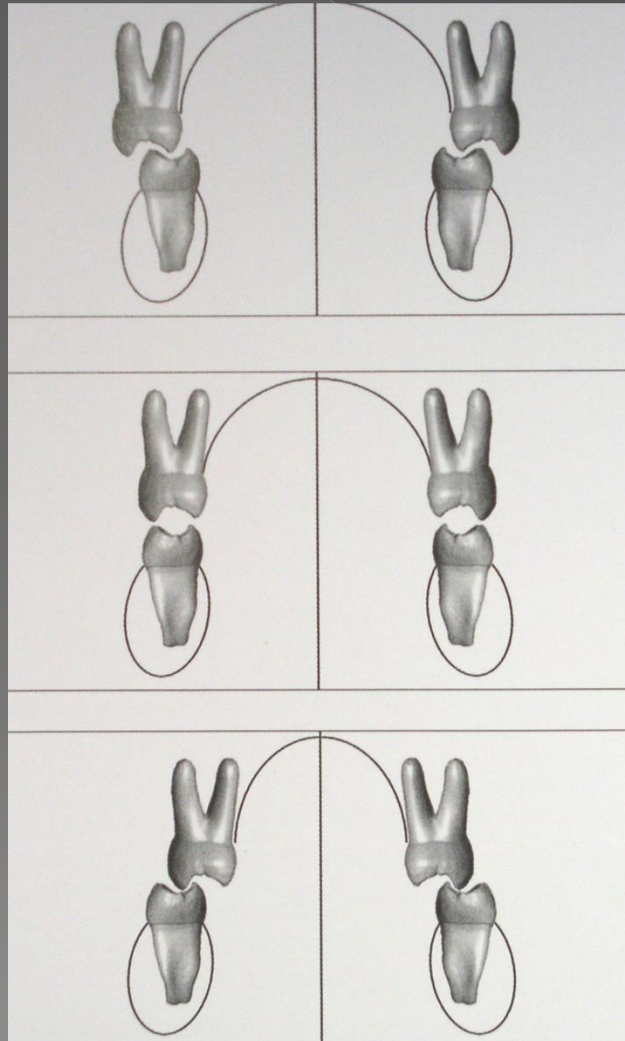


Posterior / Lateral Crossbite

Crossbite's Classification:

- ❑ Dento-alveolar crossbite.
- ❑ Skeletal crossbite.
- ❑ Functional crossbite.

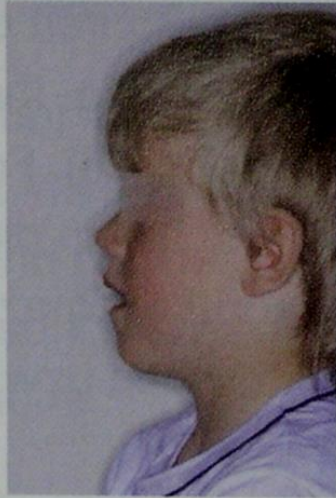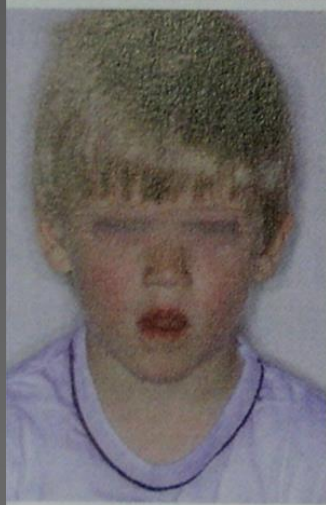Postural Classification



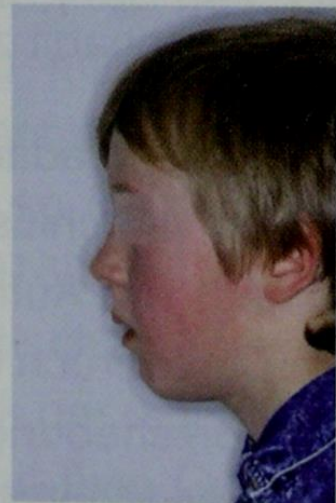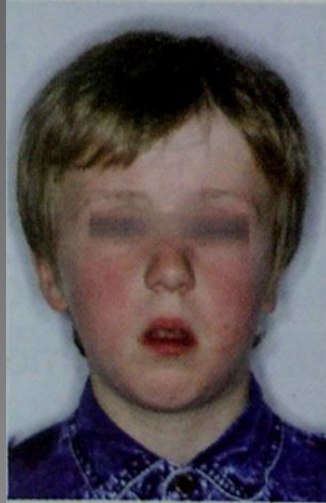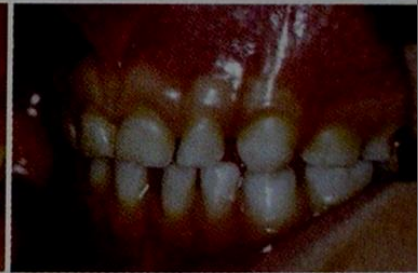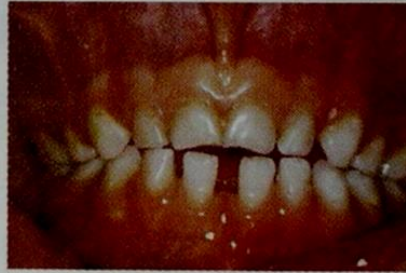Possible causes of lateral crossbites:

- Prolonged retention of primary teeth/tooth
- Space deficiency (caries, early loss, ectopic eruption,...)
- Arch tooth-size discrepancy
- Premature contacts
- Supernumerary teeth
- Bad oral habits (mouth breathing, ...)
- Skeletal

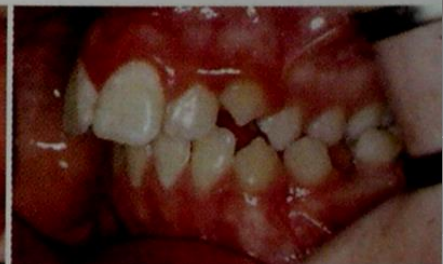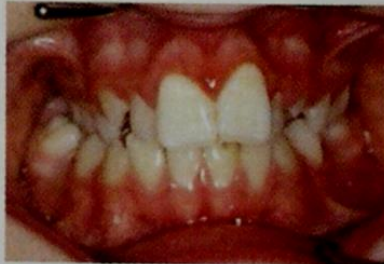Mouth breathing



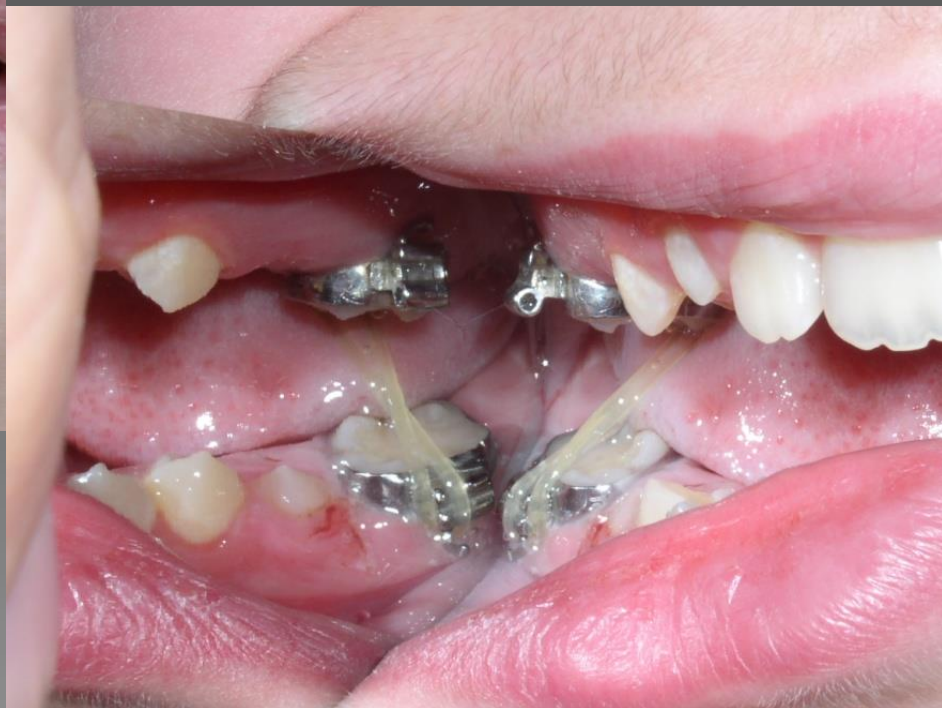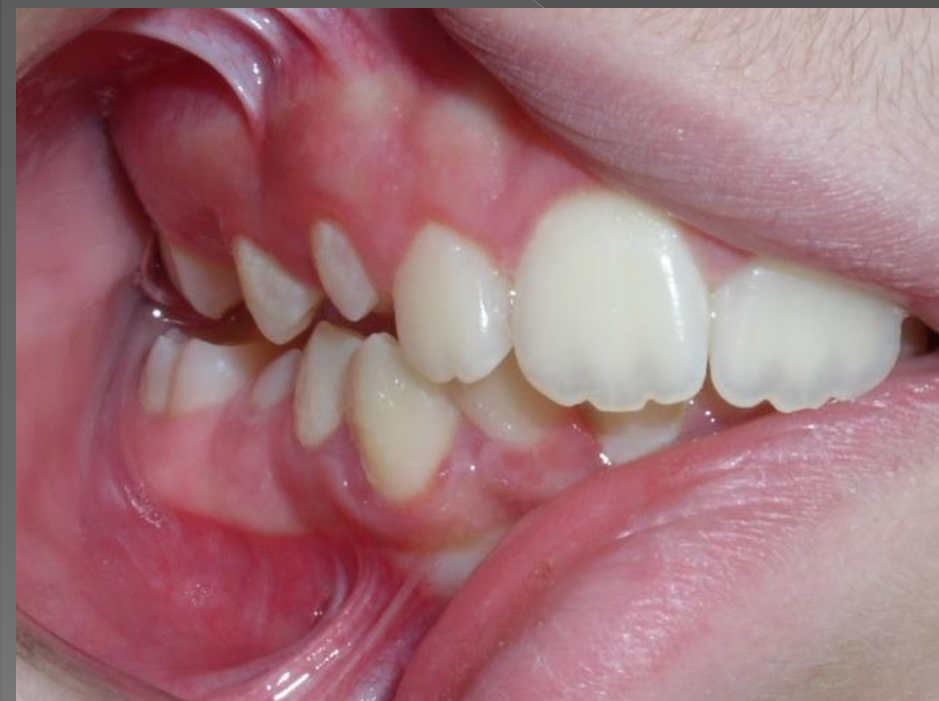4 Jahre

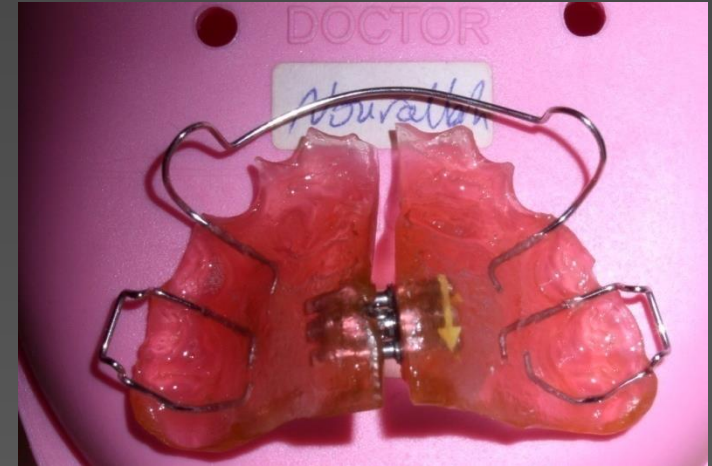
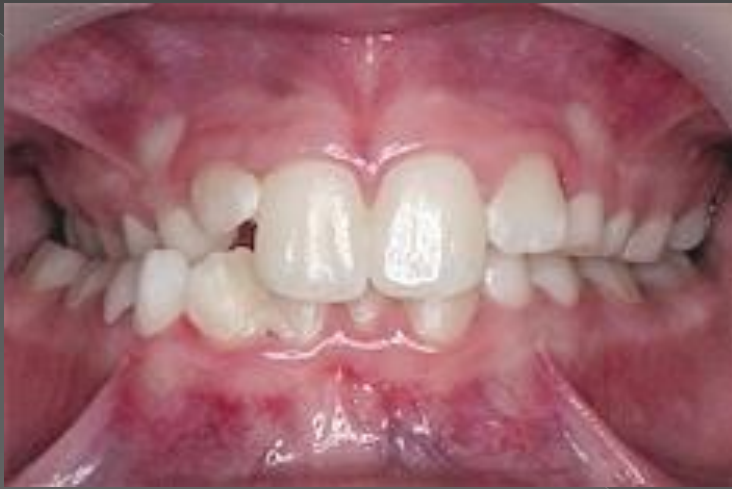

11 Jahre

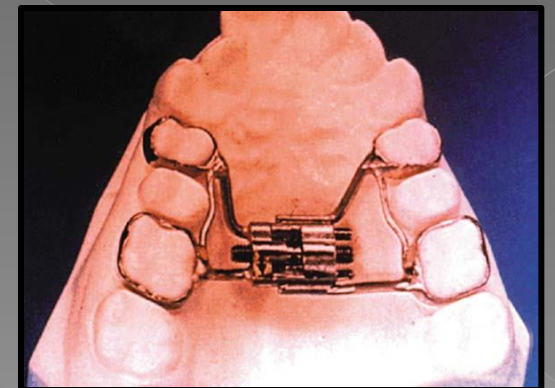
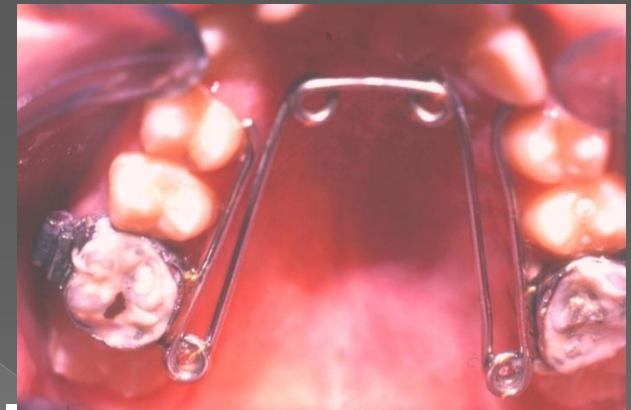


معالجة العضة المعكوسة الجانبية

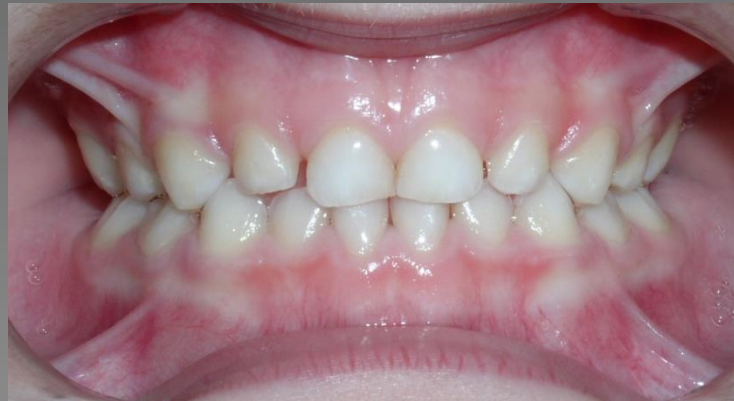
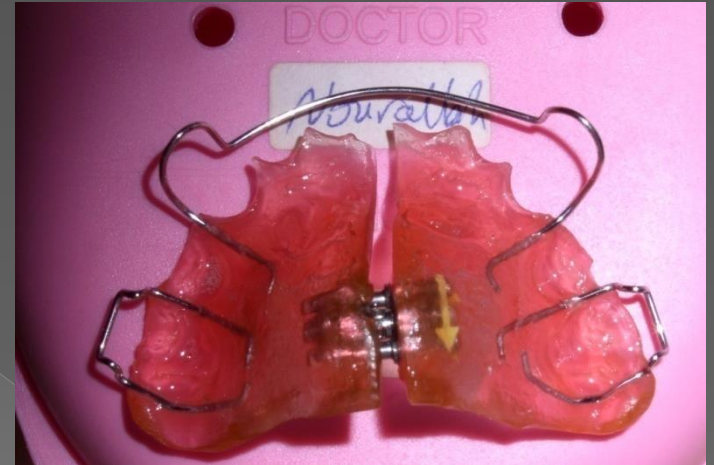
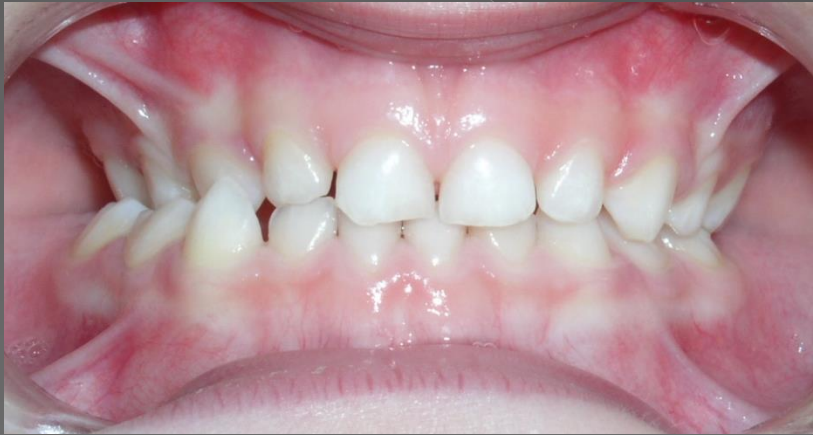

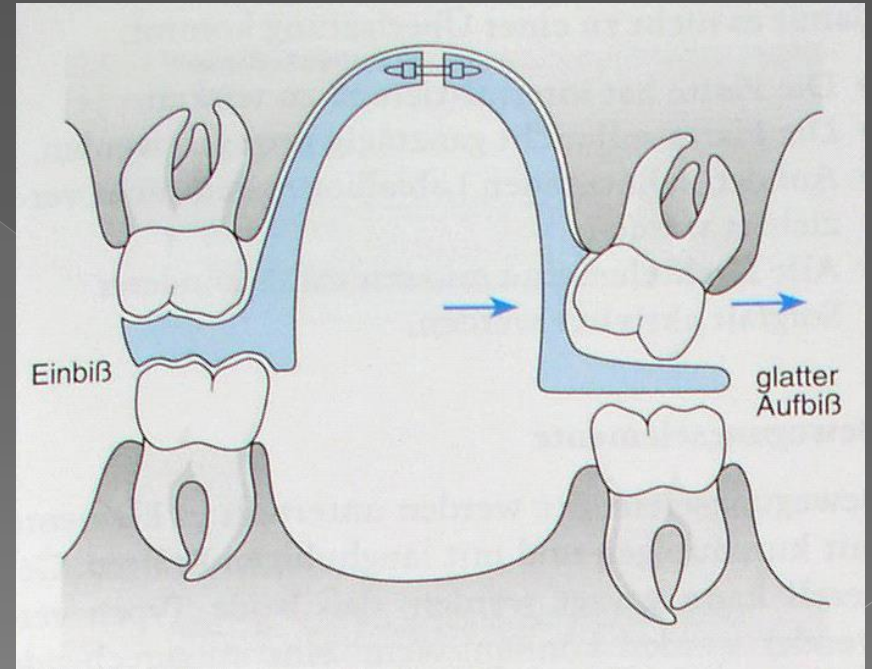
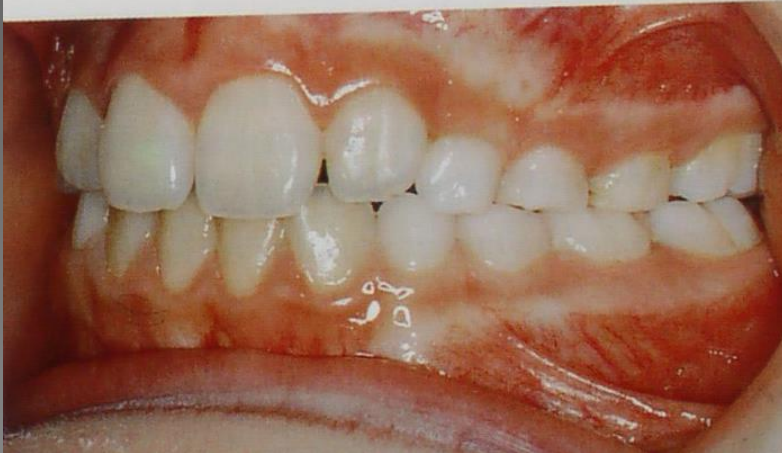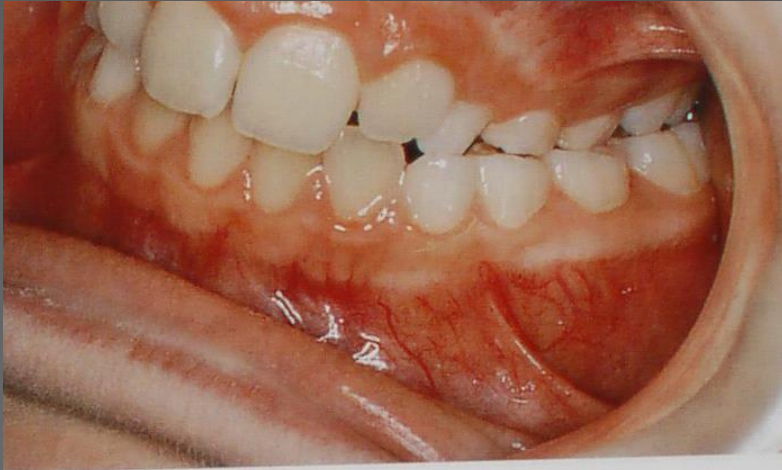- Possible treatment choices (mixed/permanent):
 - > Removable expansion – slow expansion
 - > Fixed expansion – slow expansion (Quad-Helix, W-arch)
 - > Fixed expansion – rapid expansion (RPE)

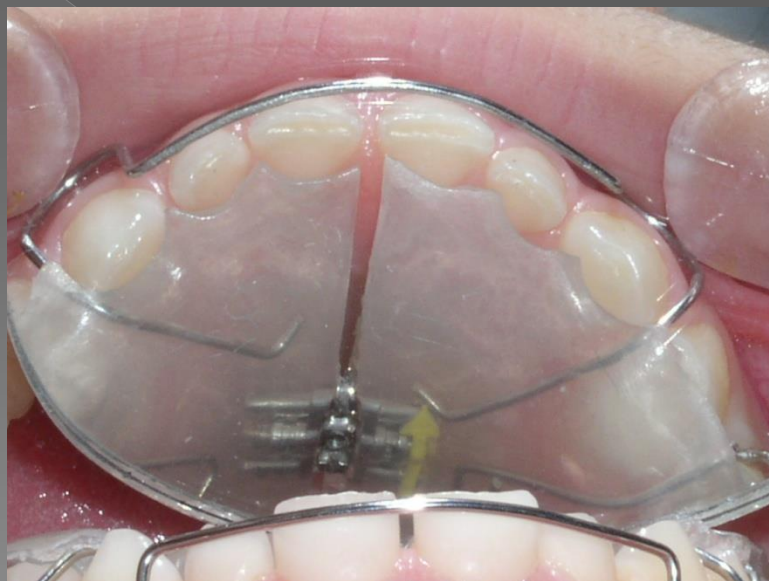
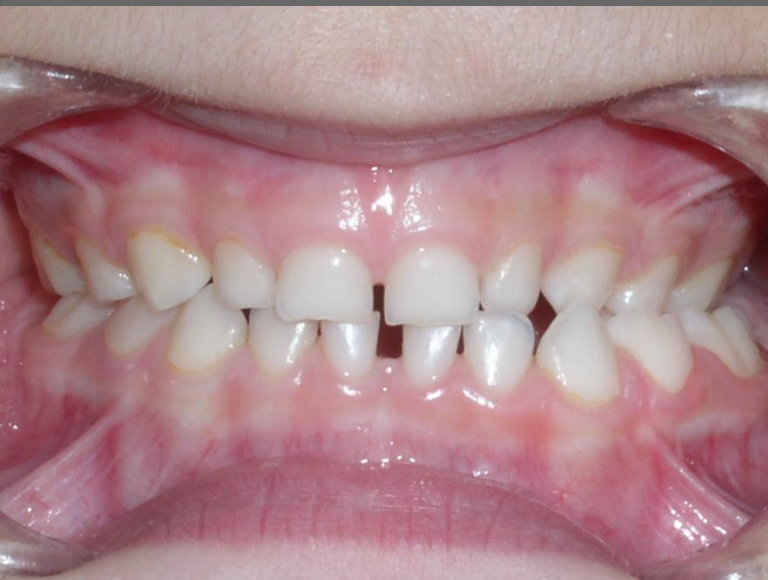
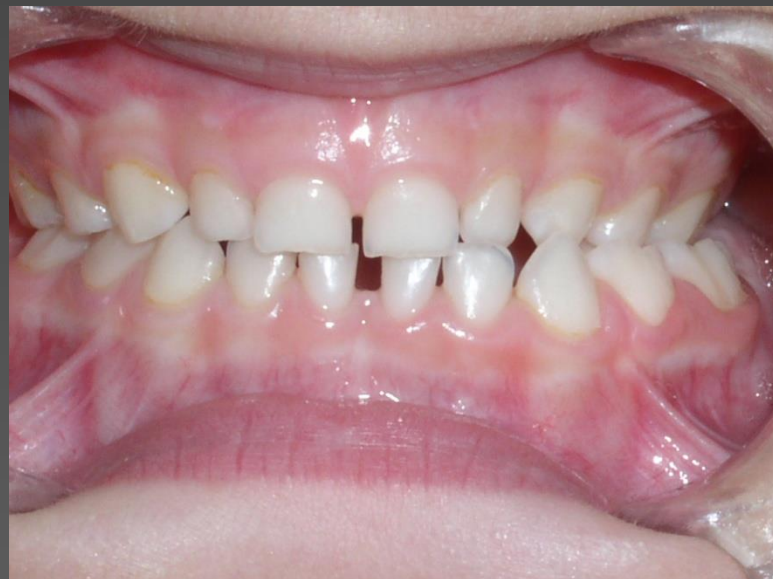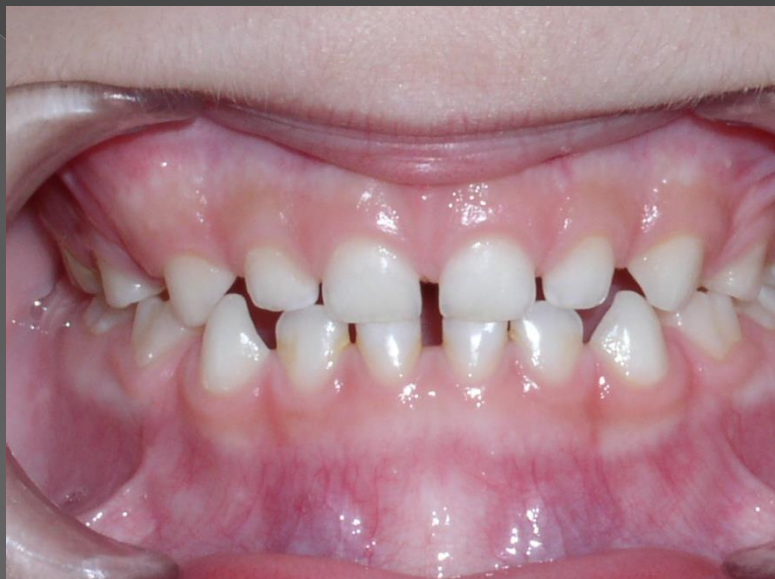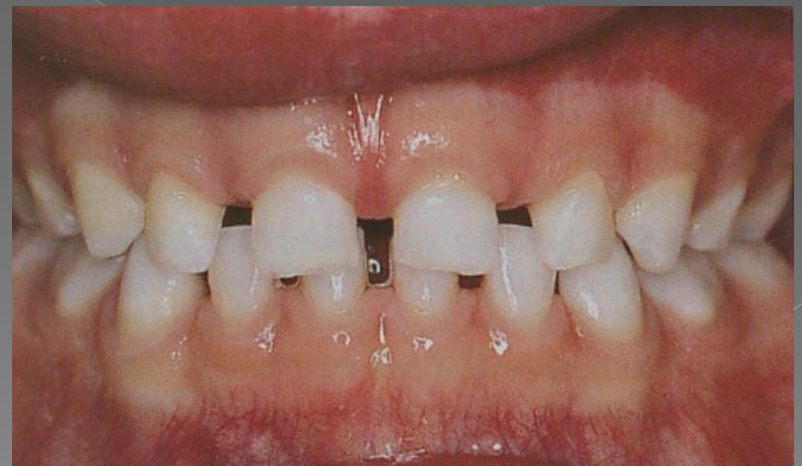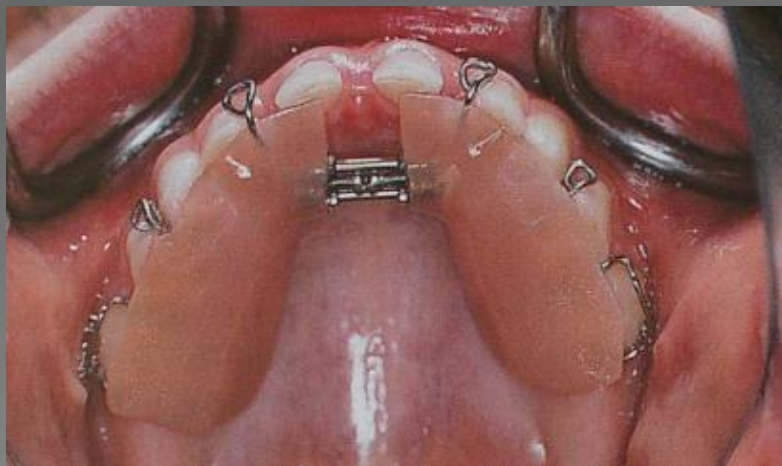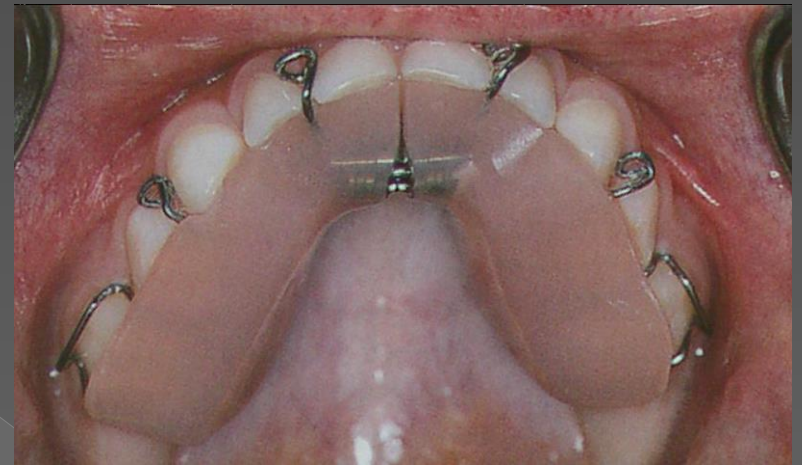
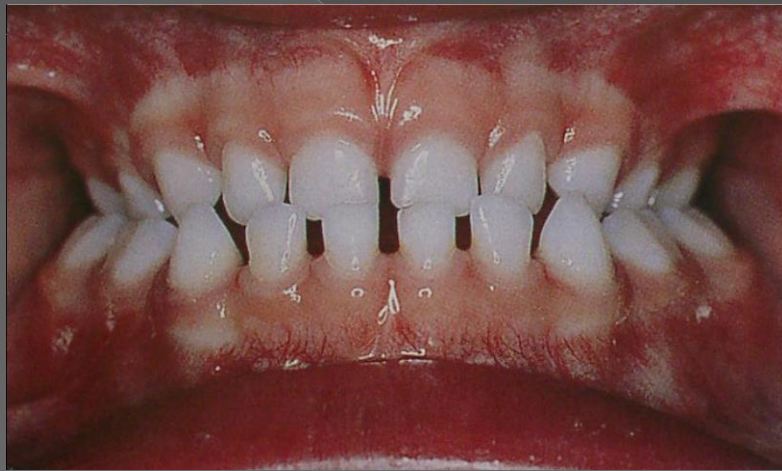معالجة العضة المعكوسة الجانبية



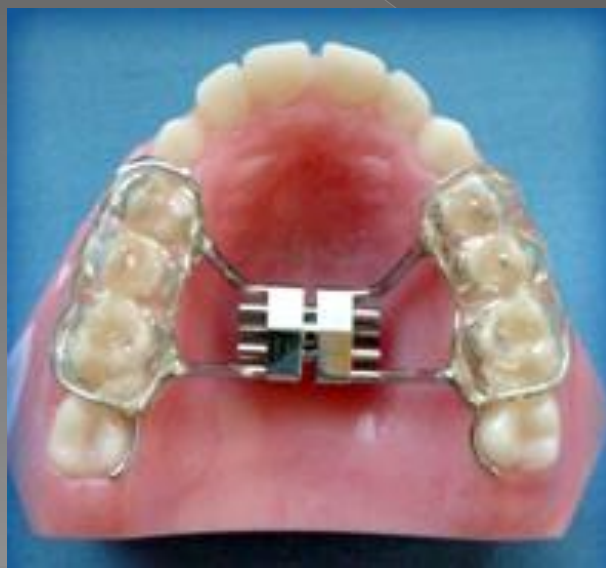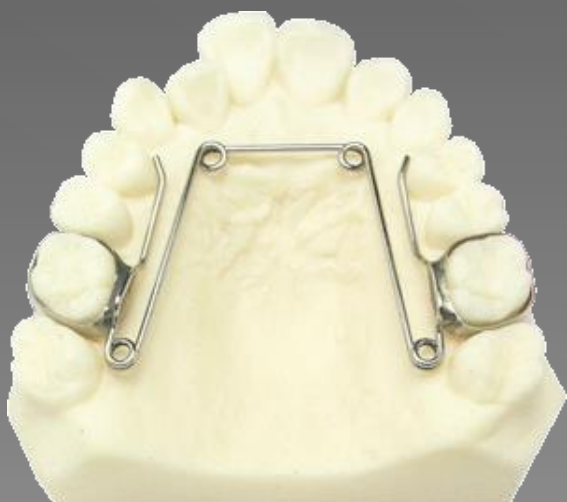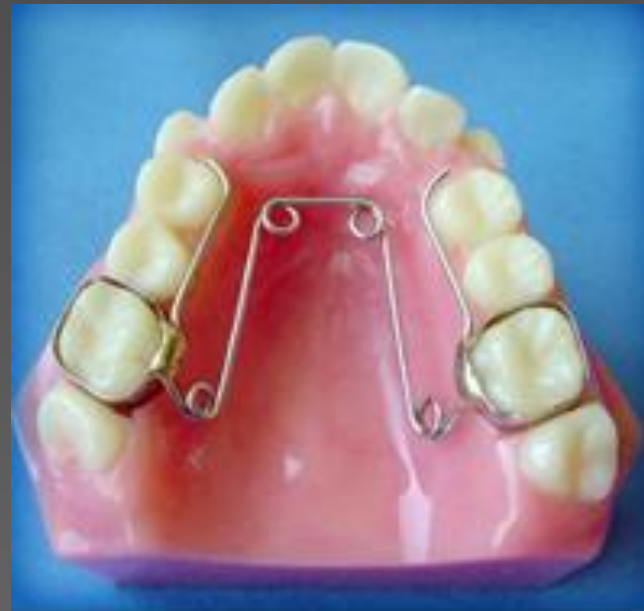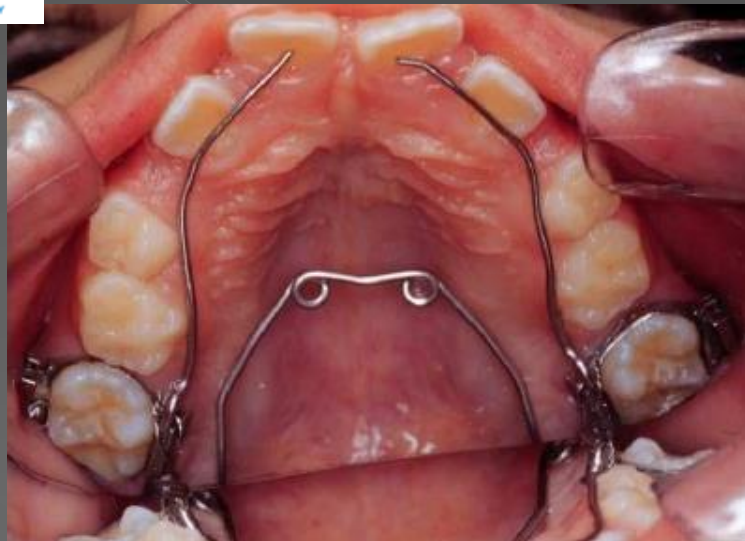
معالجة العضة المعكوسة الجانبية



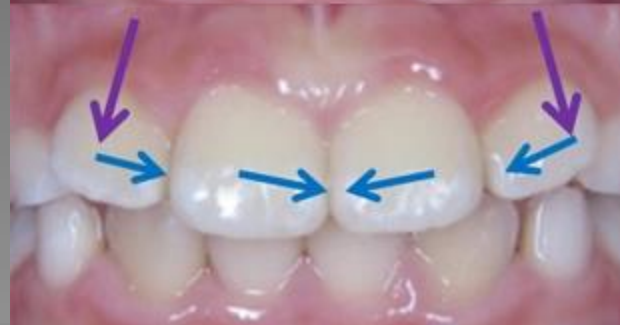
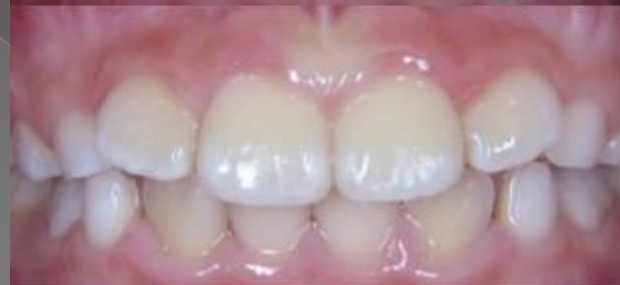
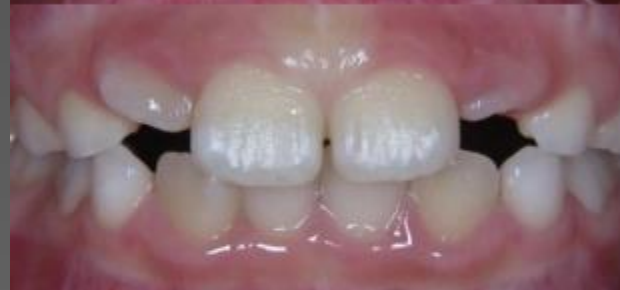
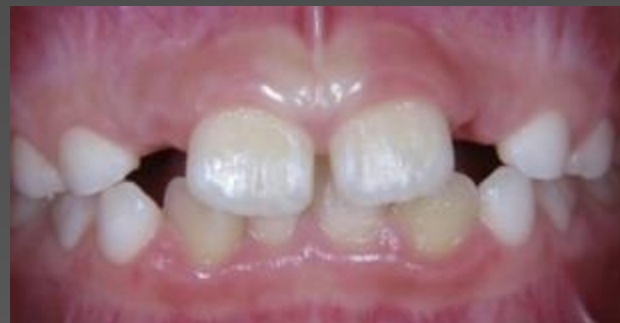
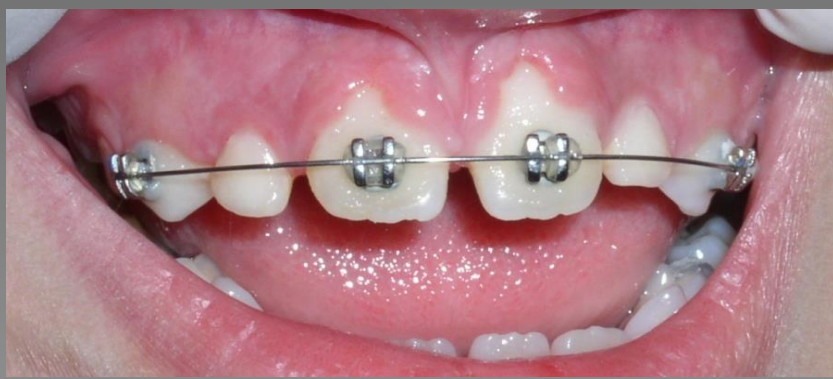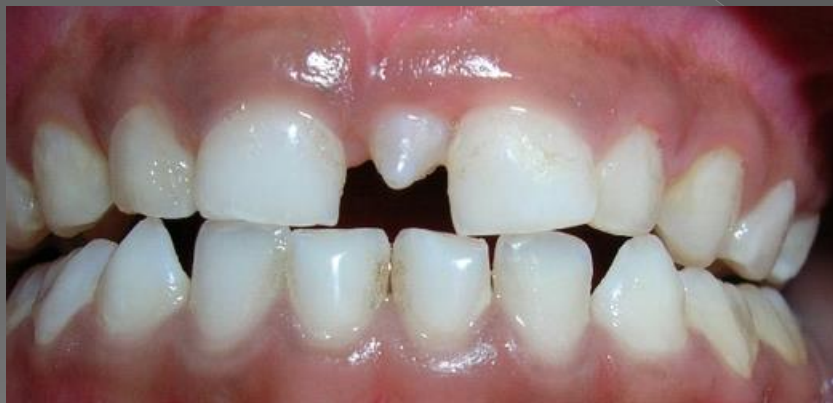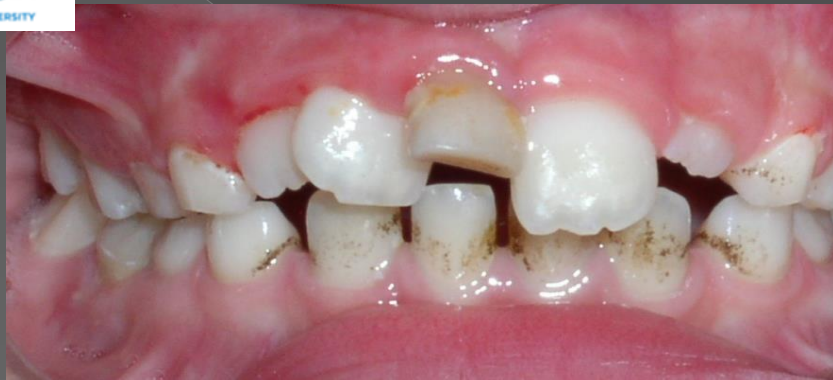Posterior crossbite treat. choices

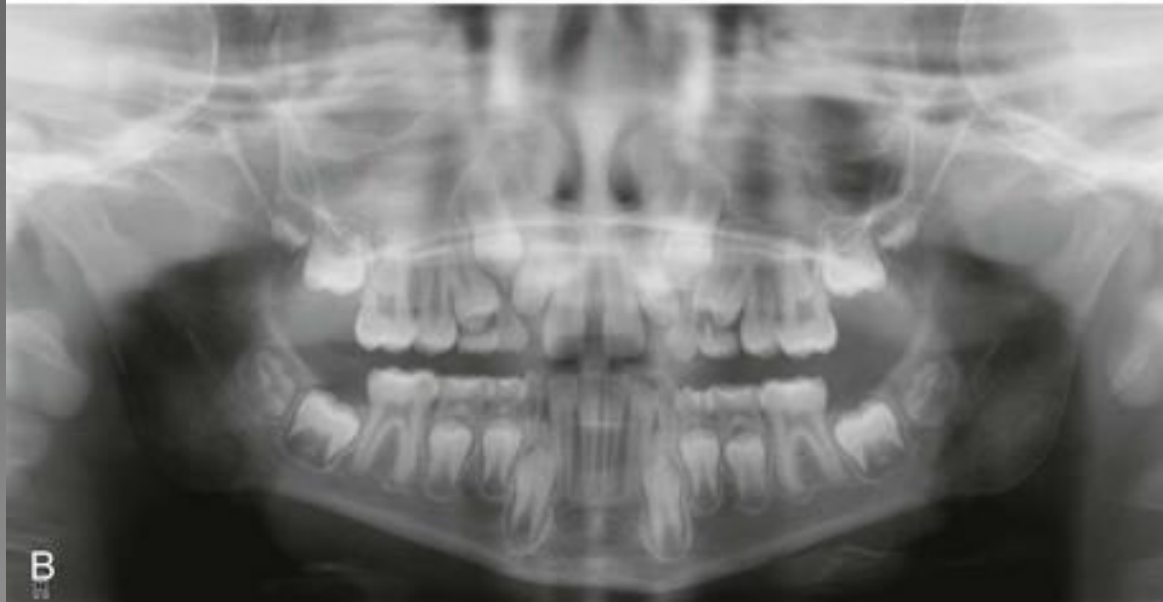
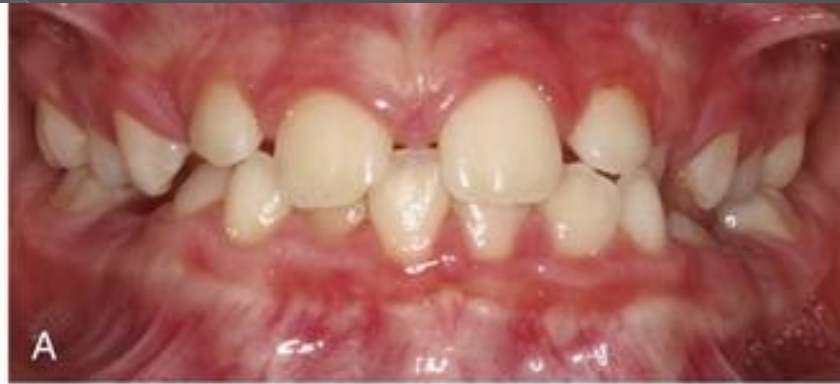
Diastemas



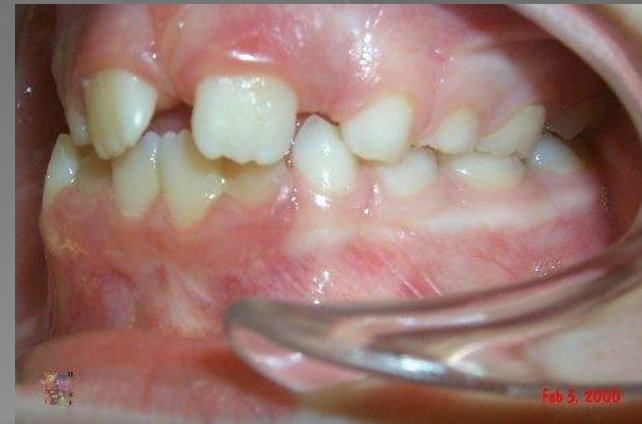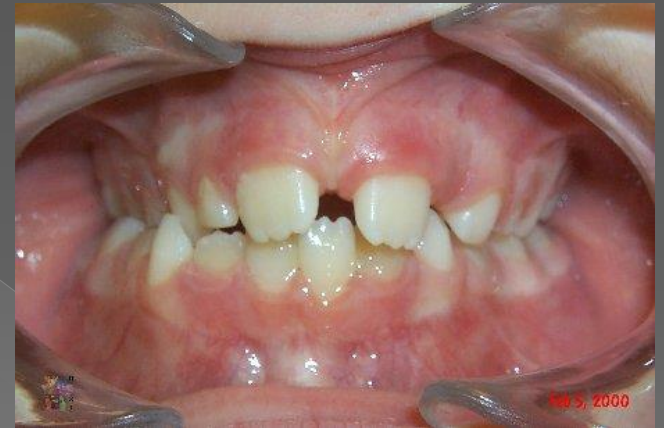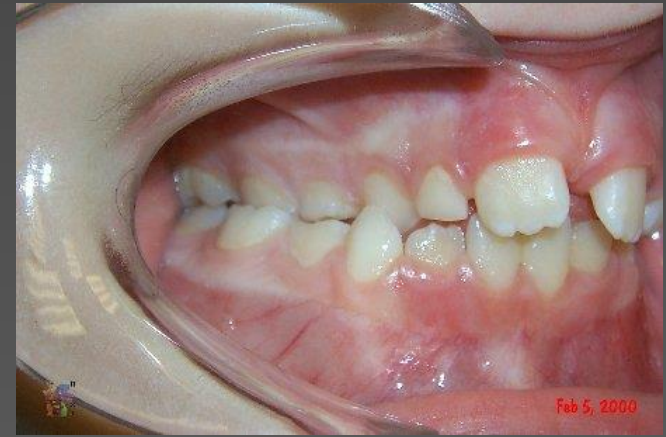Ugly Duckling Stage

مرحلة البطة البشعة



Compound cases

Crossbite+diastema

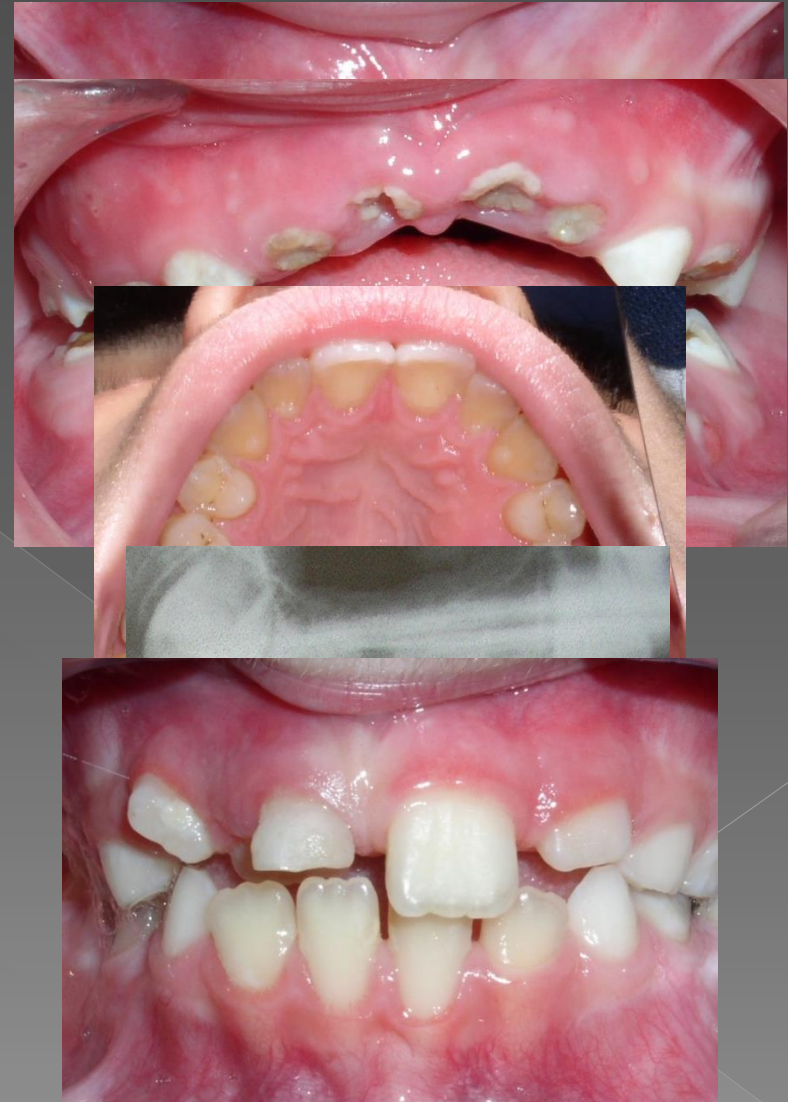

Space loss

Space regaining

Causes of space loss:

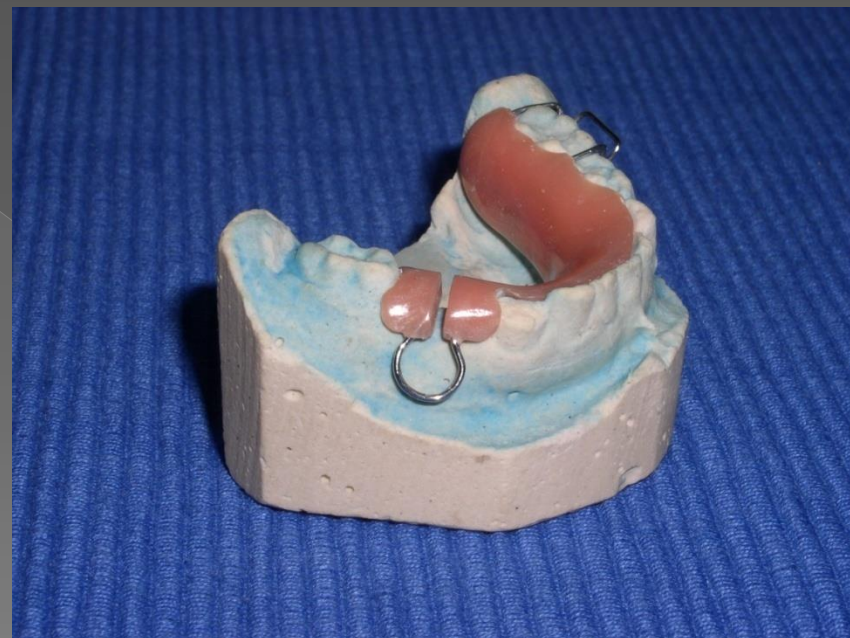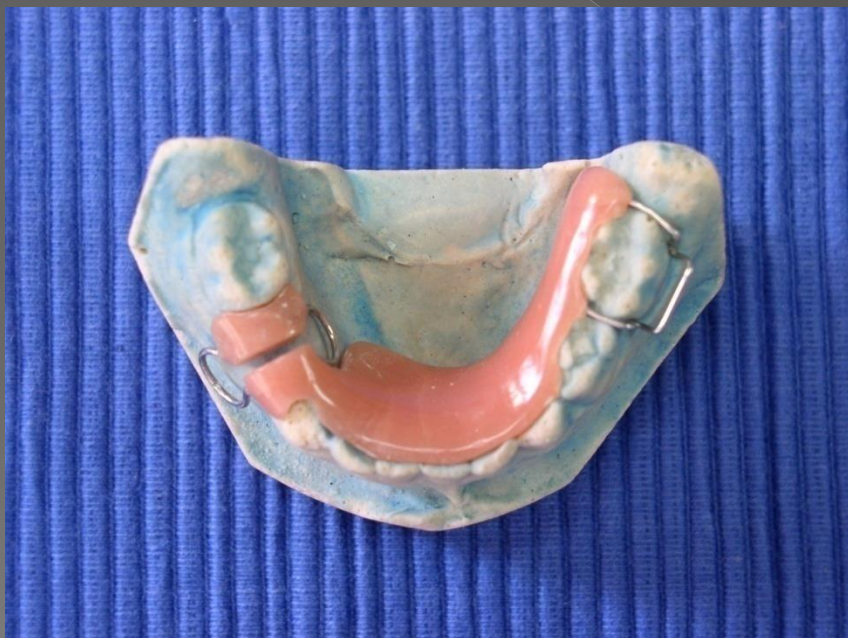- Alveolar bone-tooth size discrepancy.
- proximal caries / trauma for primary teeth
- premature loss of primary teeth/tooth.
- Ectopic eruption of FPM, or LI.
- Prolonged retention of primary teeth/tooth.



Space regaining

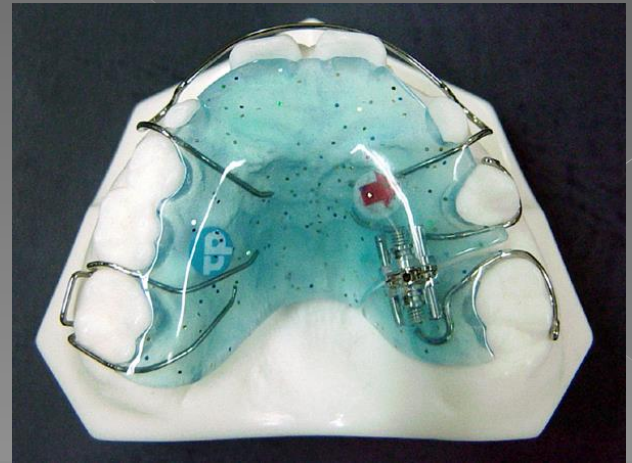
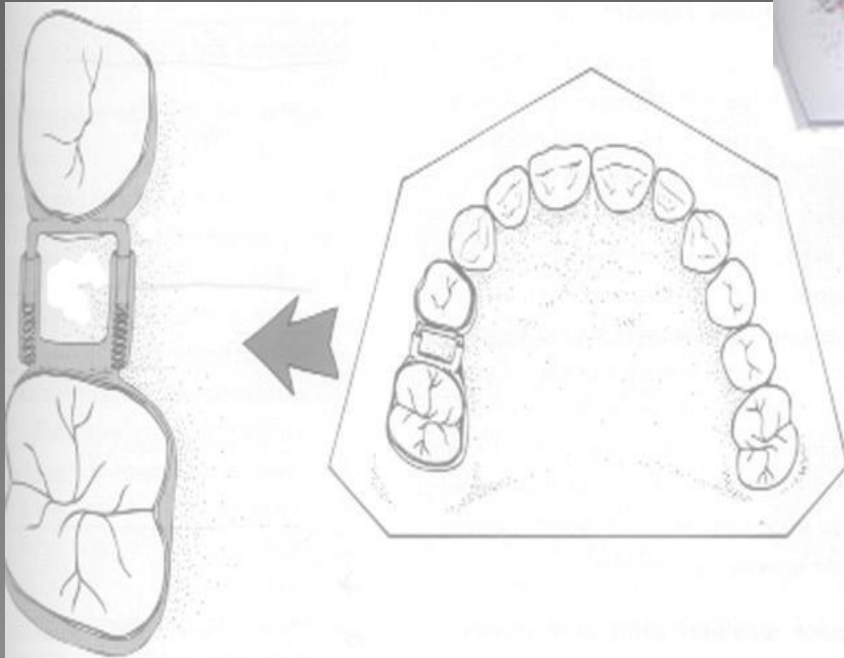
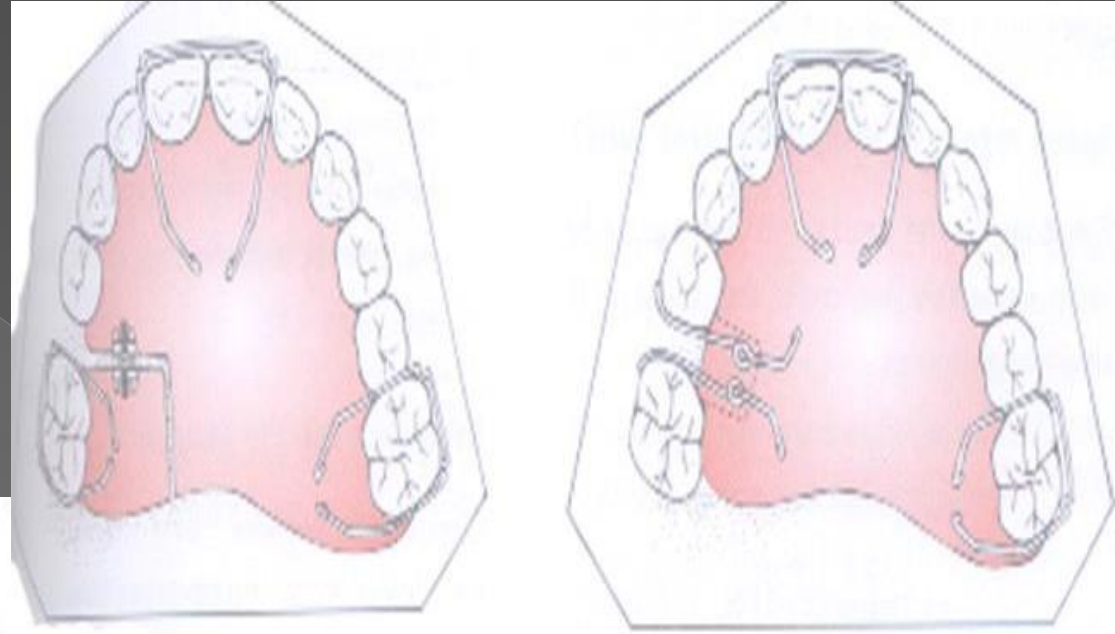
- ◉ FPM distalization, FPM uprighting
- ◉ Anterior inclination of incisors
- ◉ Teeth material reduction
- ◉ Arch expansion
- ◉ Teeth unit extraction??

Space regaining السرّج المشطور

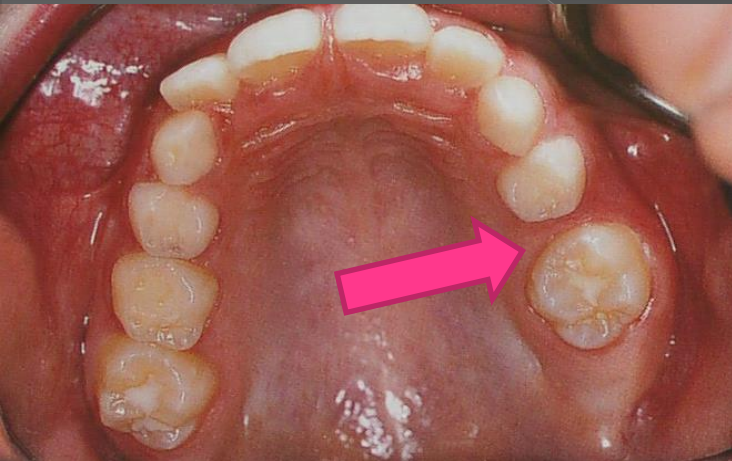


Space regaining

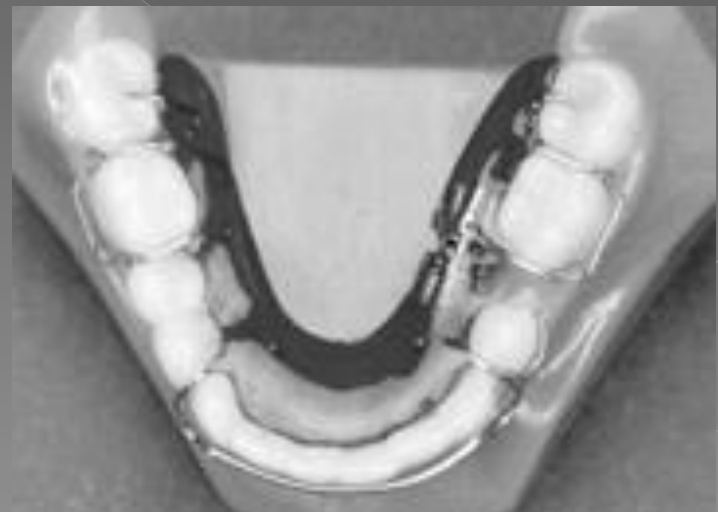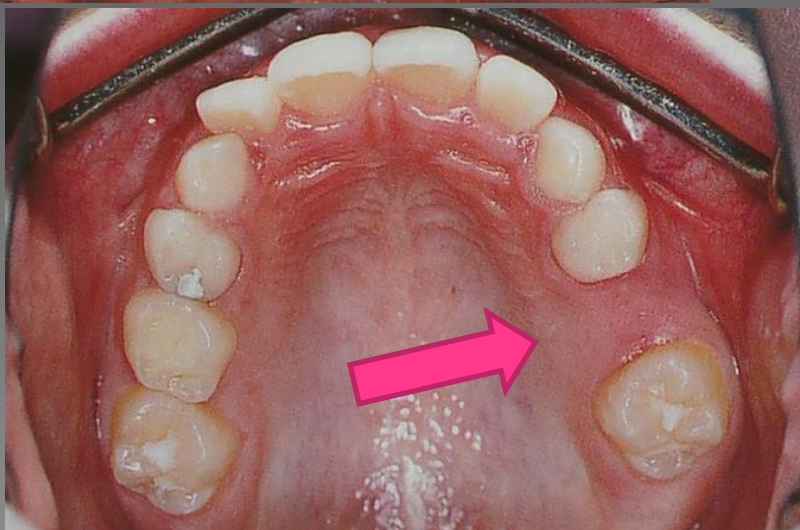
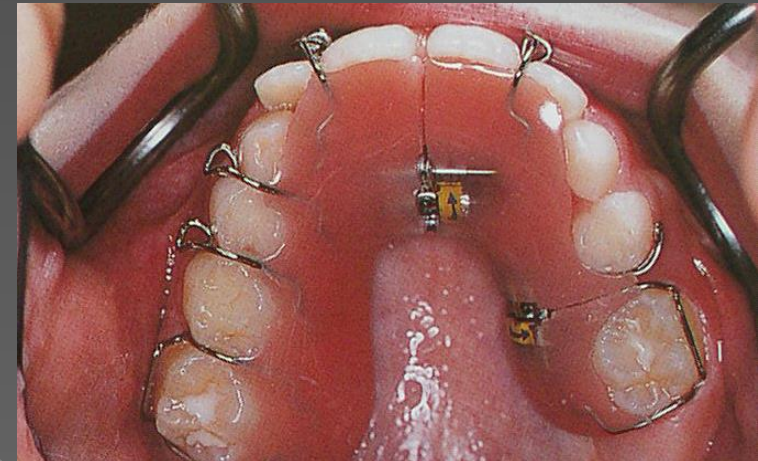
- FPM uprighting / distalization



Molar distalization

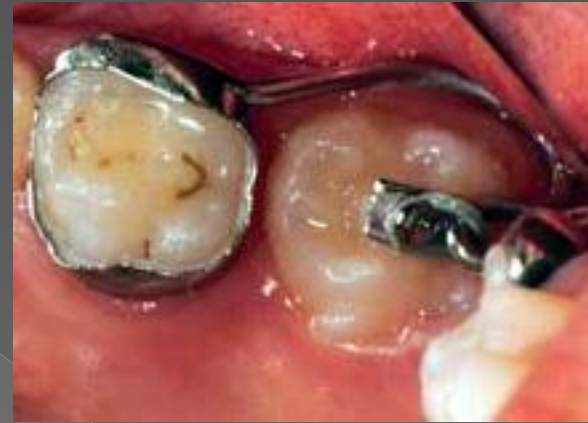
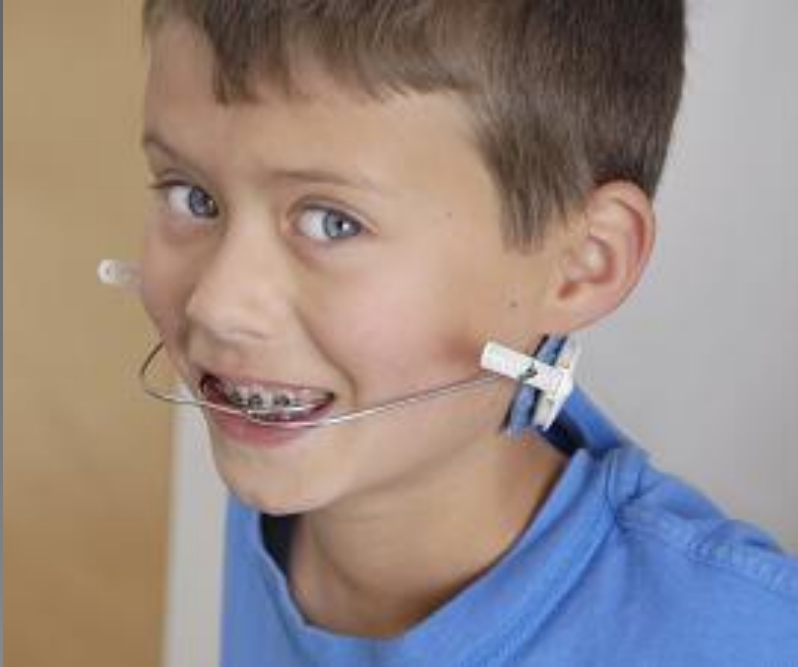
- Removable space regainer with jackscrew.



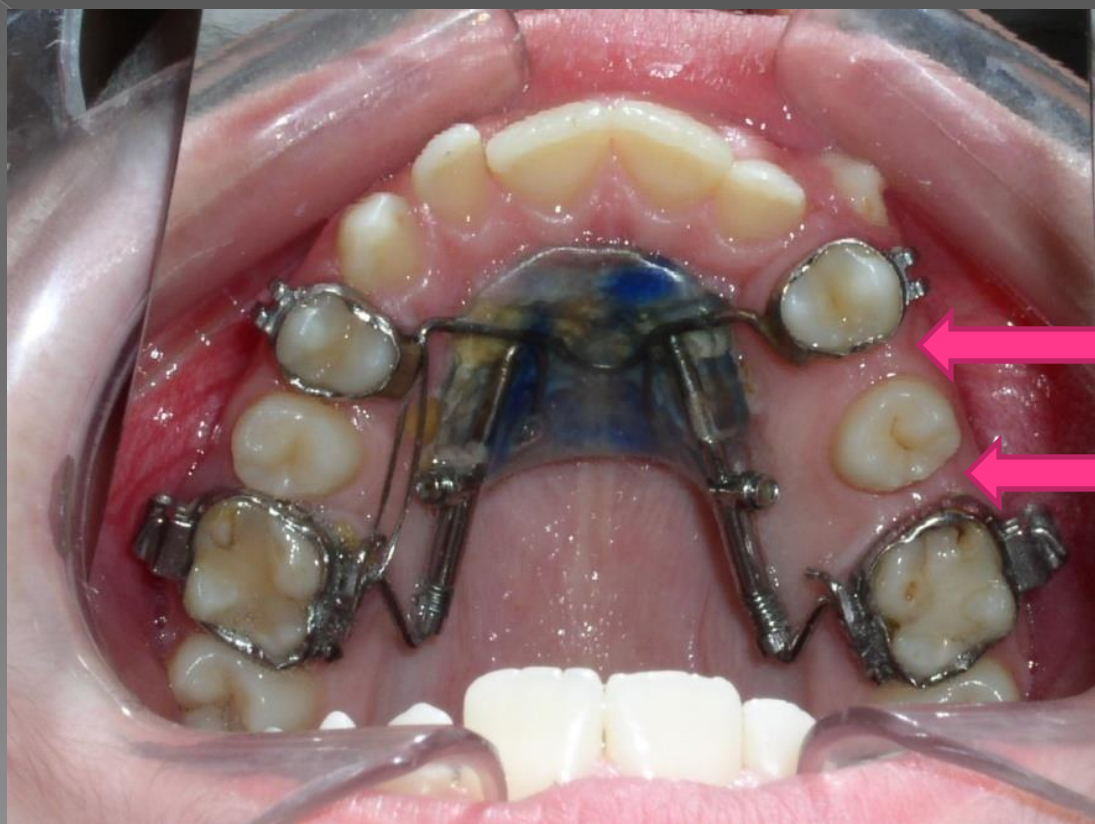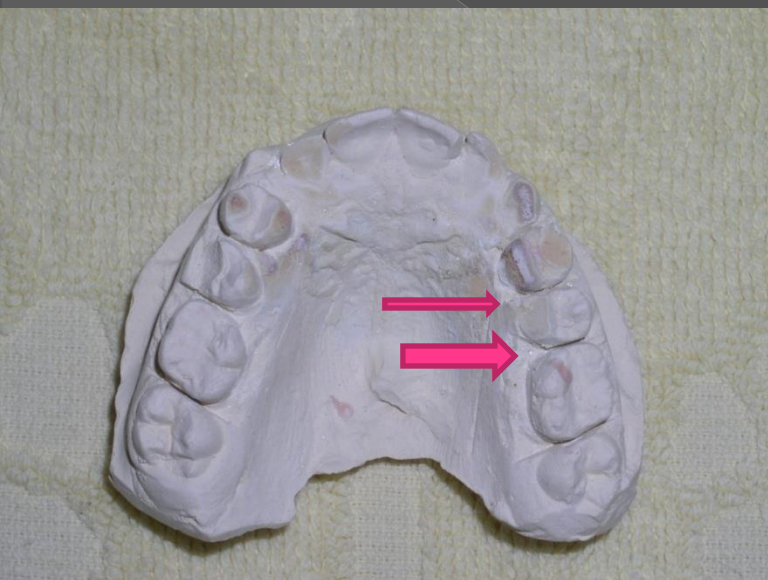Molar distalization/uprighting

Head gear

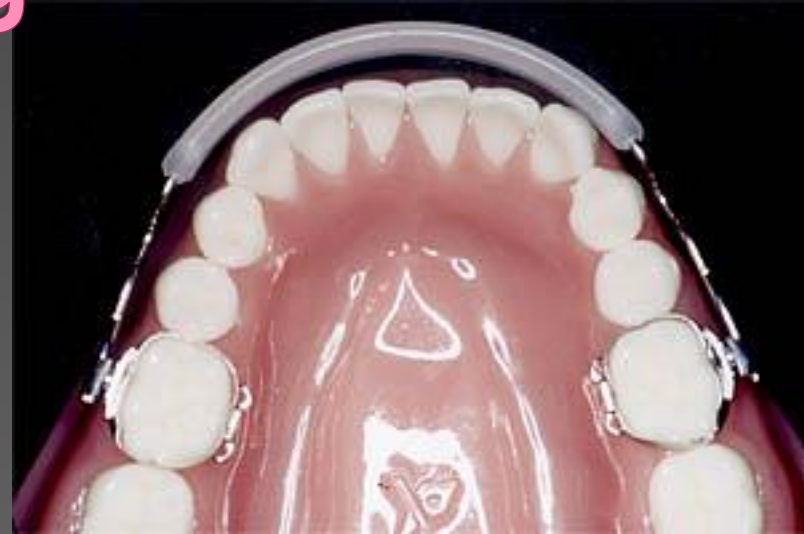
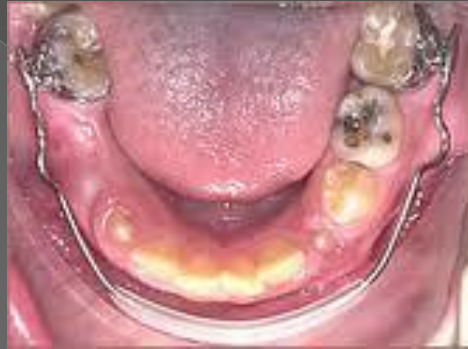
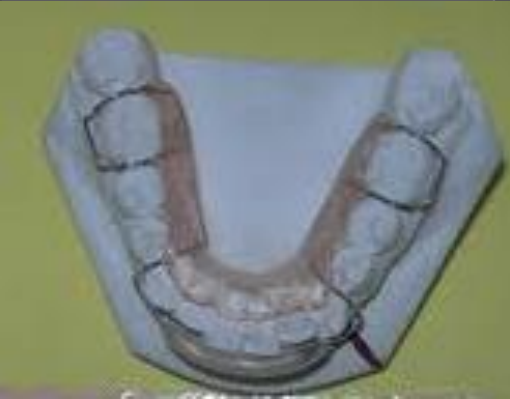Halterman
device

Distal jet



Space regaining

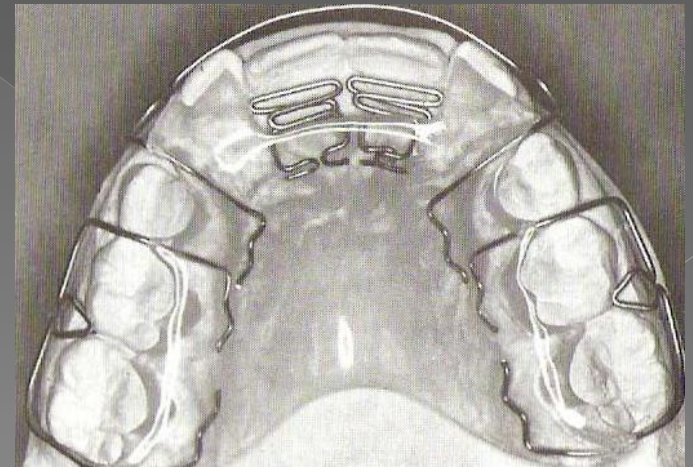


◉ Space regaining

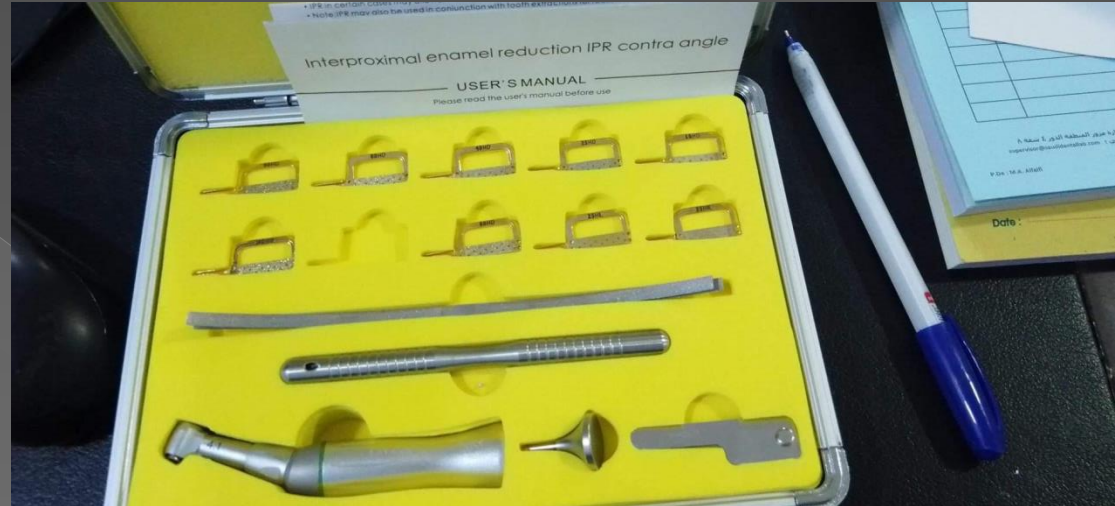
- > for moderate space regaining in the mandibular arch, up to 1mm, it may be accomplished with a lip bumper

Space regaining

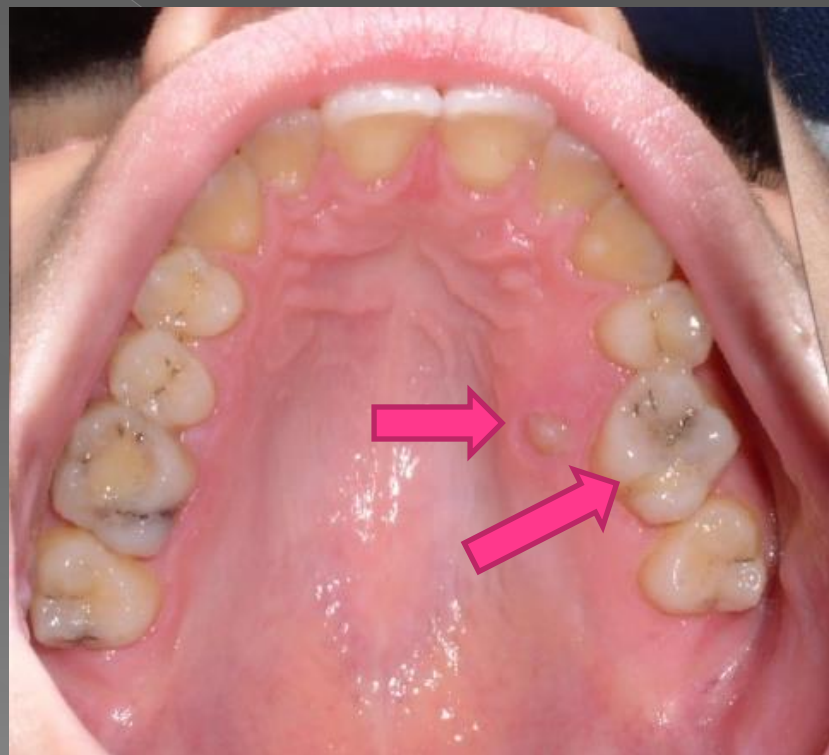
- ◉ FPM distalization, FPM uprighting
- ◉ Anterior inclination of incisors
- ◉ Teeth material reduction
- ◉ Arch expansion
- ◉ Teeth unit extraction??



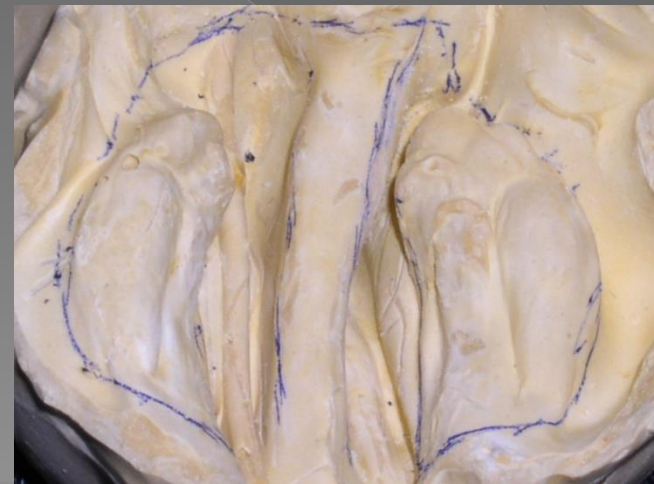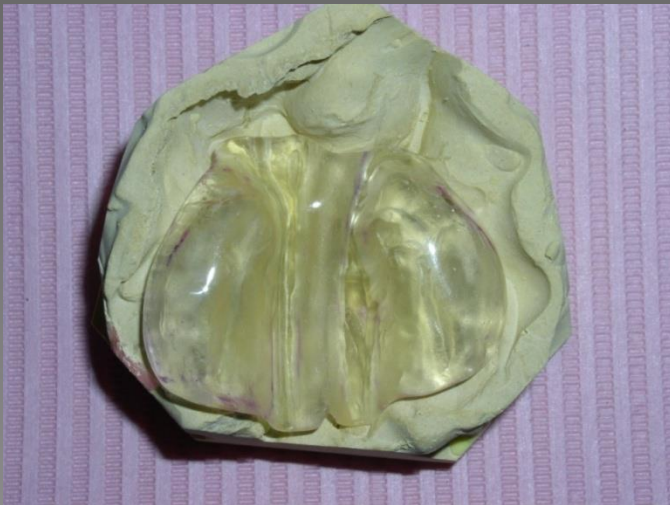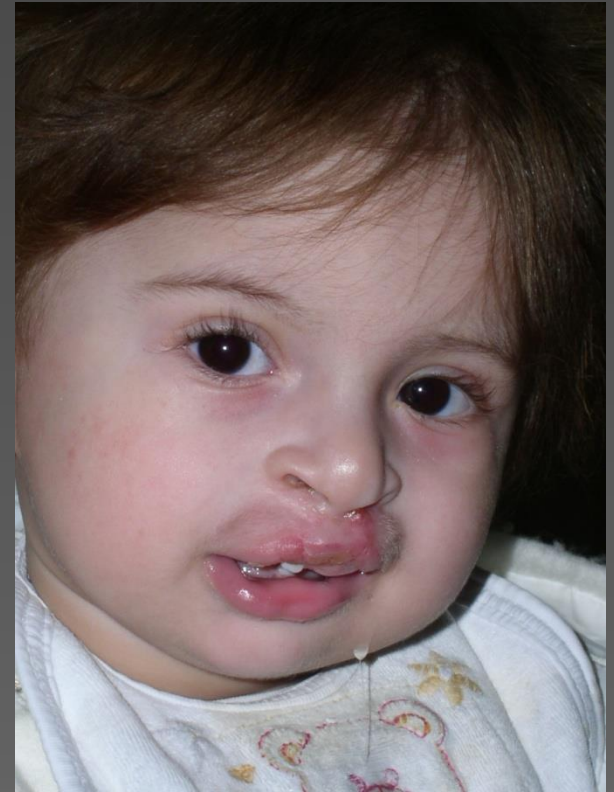
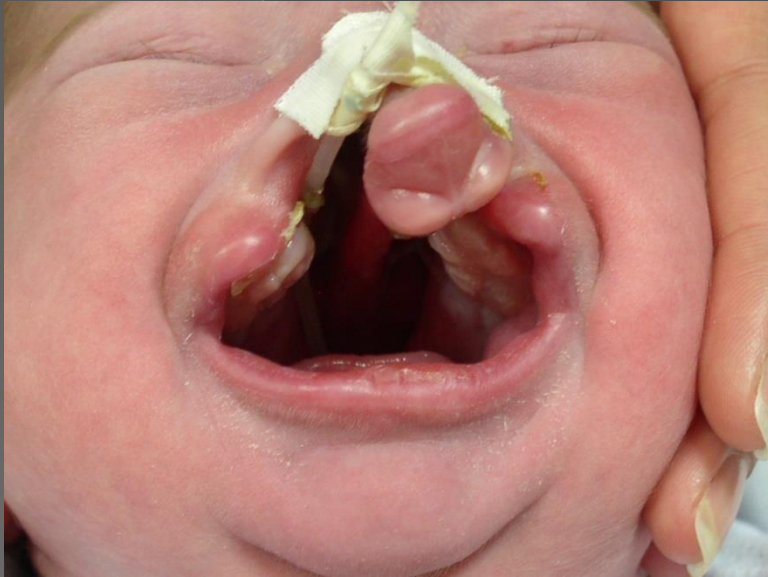مجموعة السحل الملاصق interproximal enamel reduction set



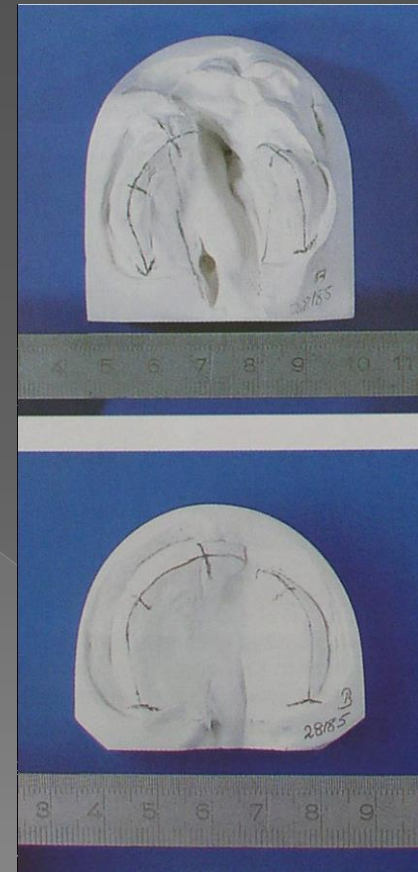
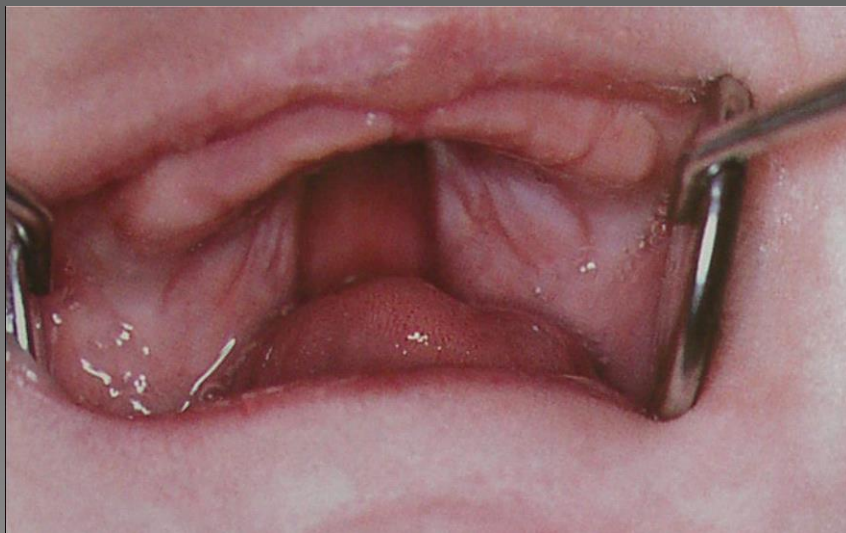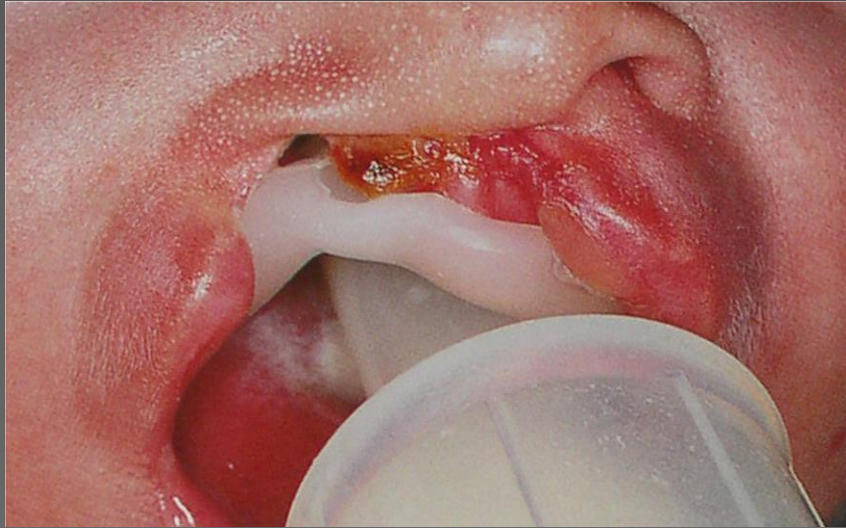Complicated cases



Cleft lip and palate



Cleft lip and palate



Serial Extraction

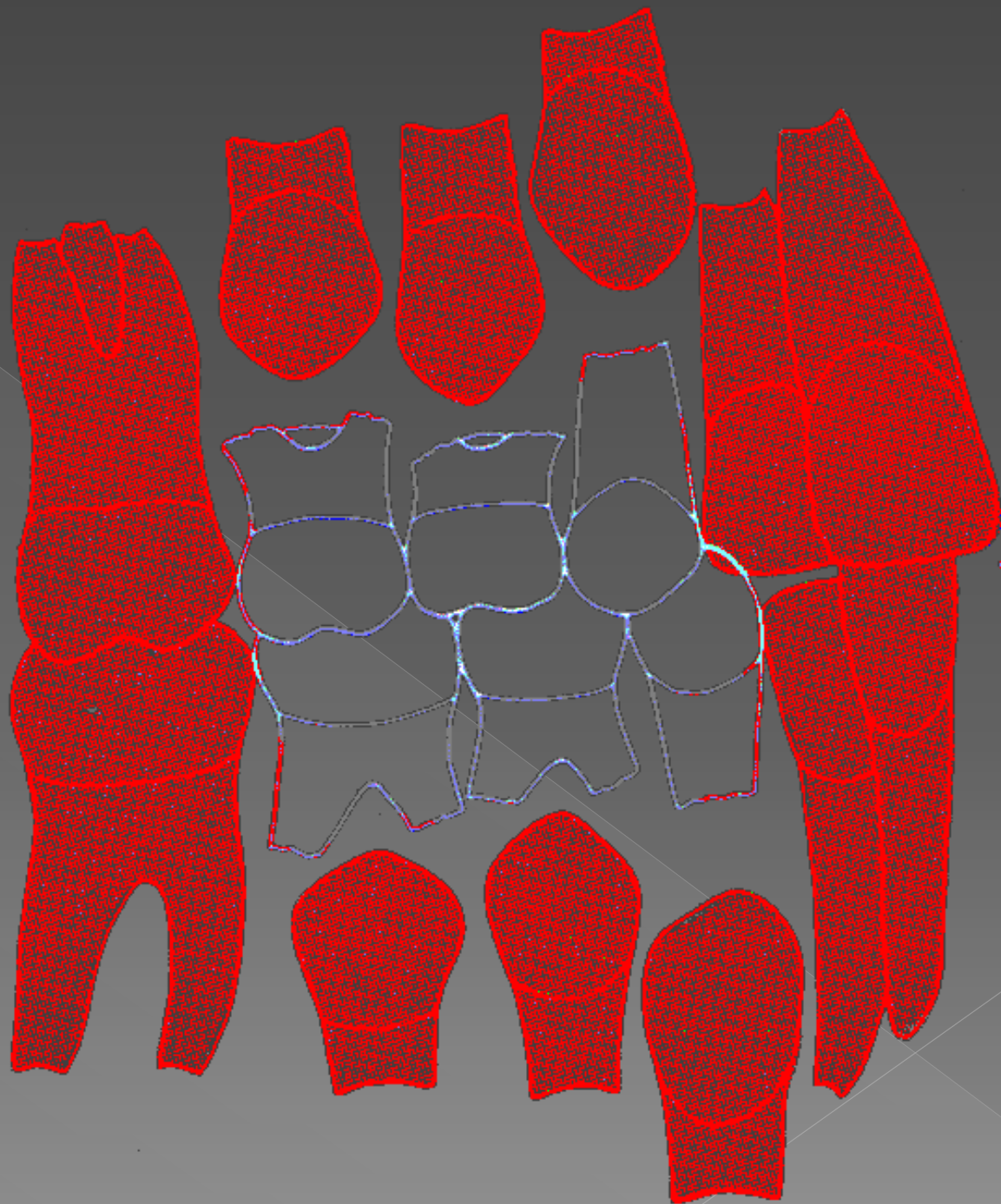
A planned sequence of tooth removal that can reduce crowding and irregularity during the transition from the primary to the permanent dentition.

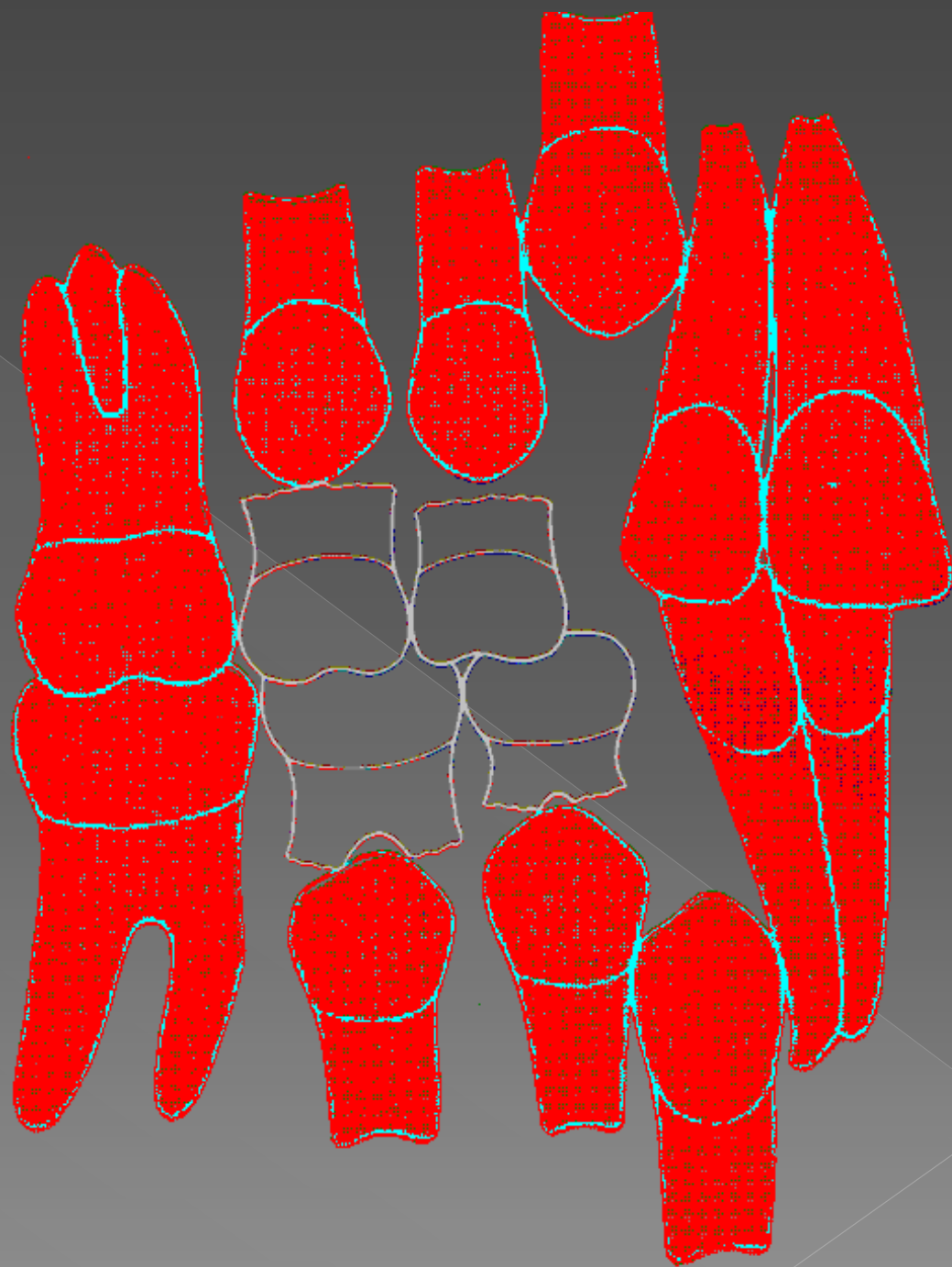
Used in severe crowding cases where transverse expansion in the mixed dentition will likely be unsuccessful.

Indications for Serial Extraction

- 1) No skeletal problem exists /Class I/
- 2) Large space discrepancy
- 3) Normal overbite


A

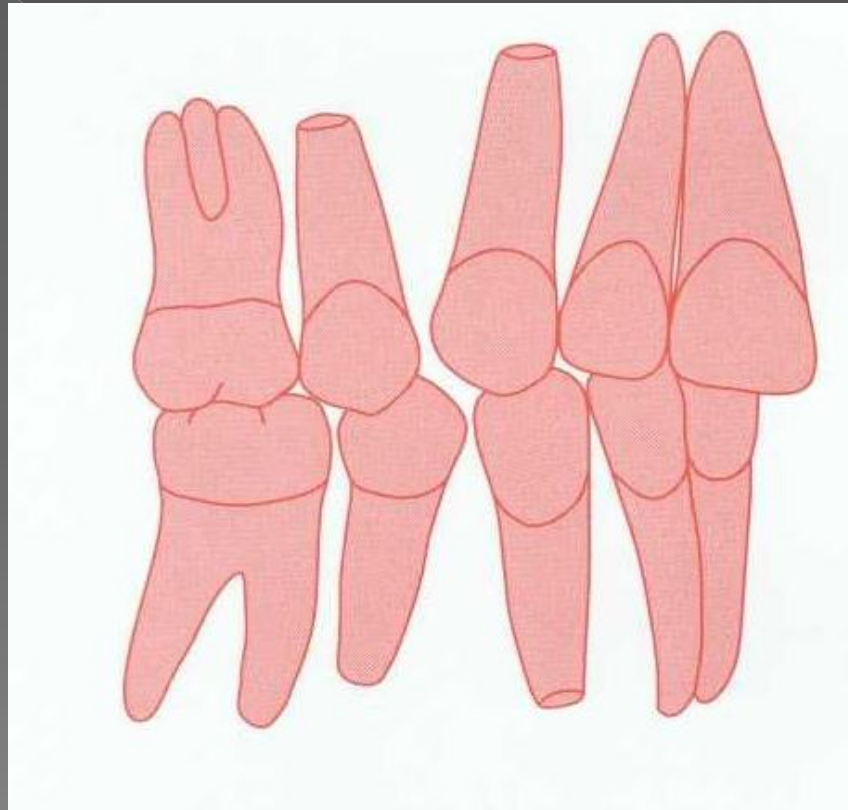




B

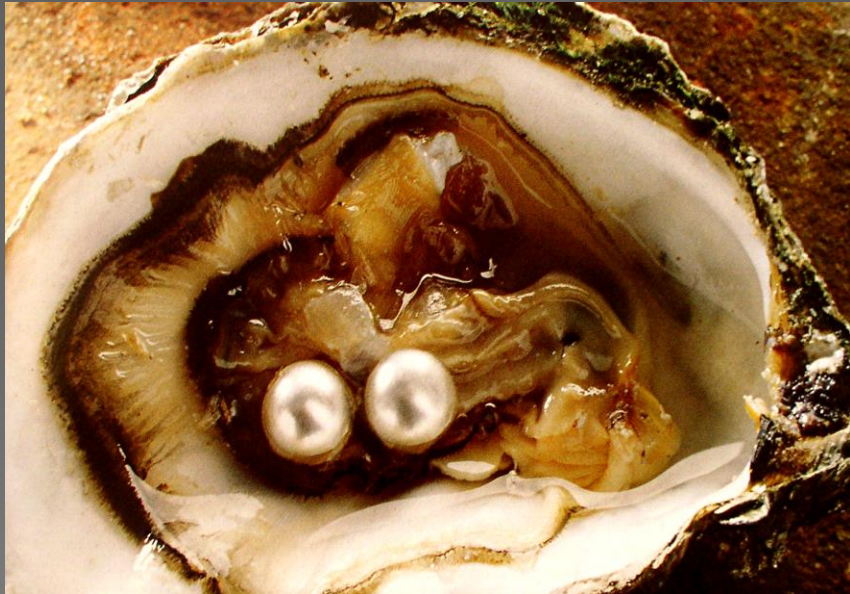C



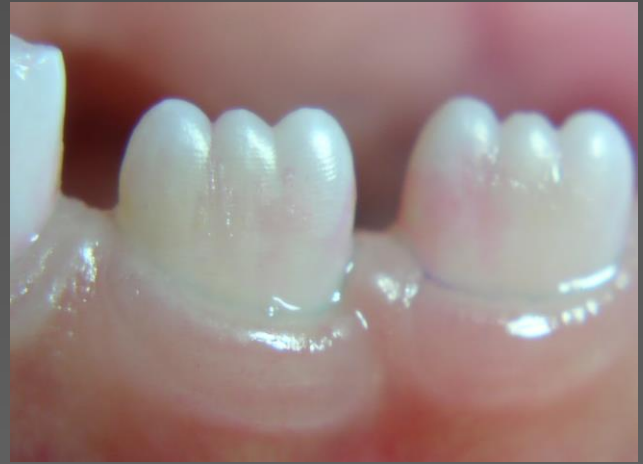



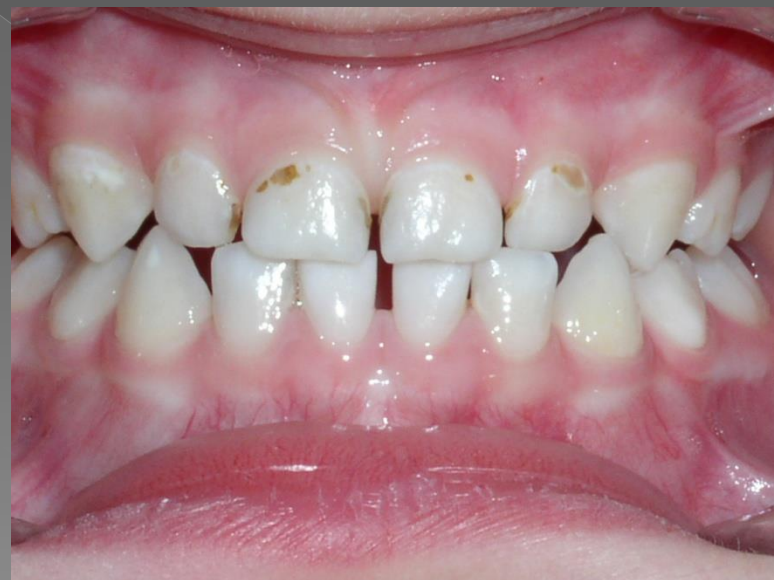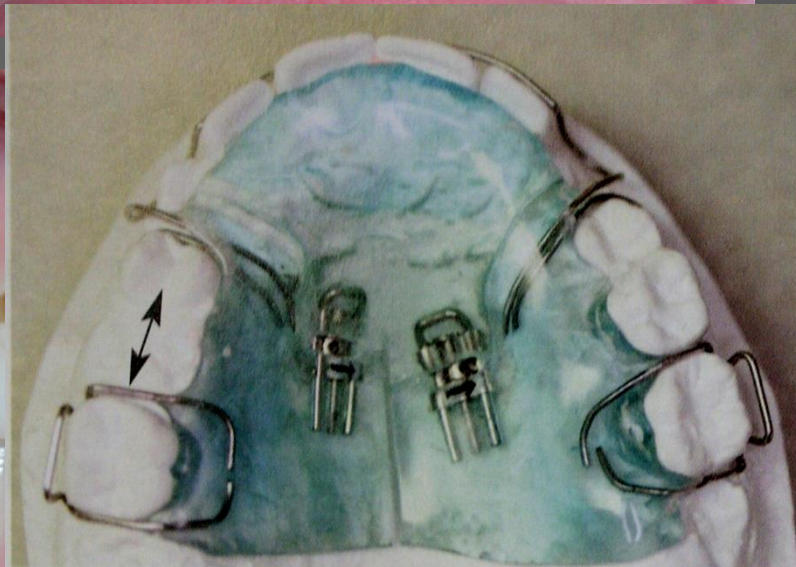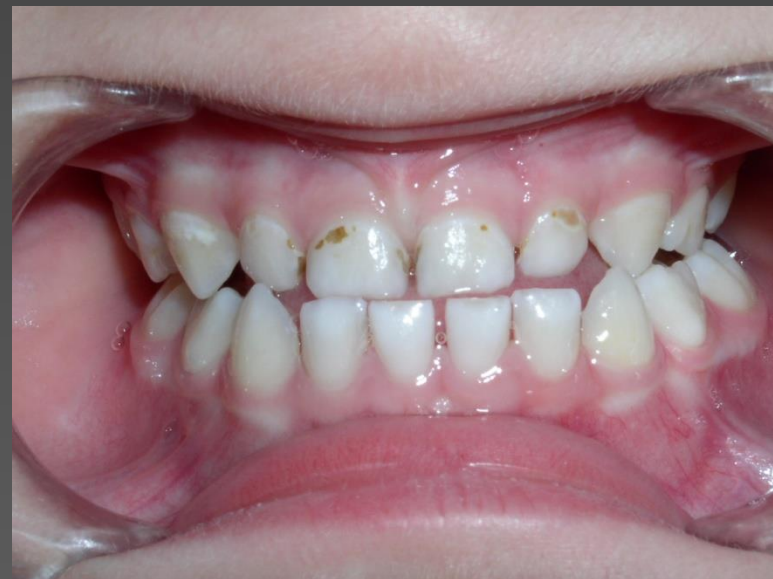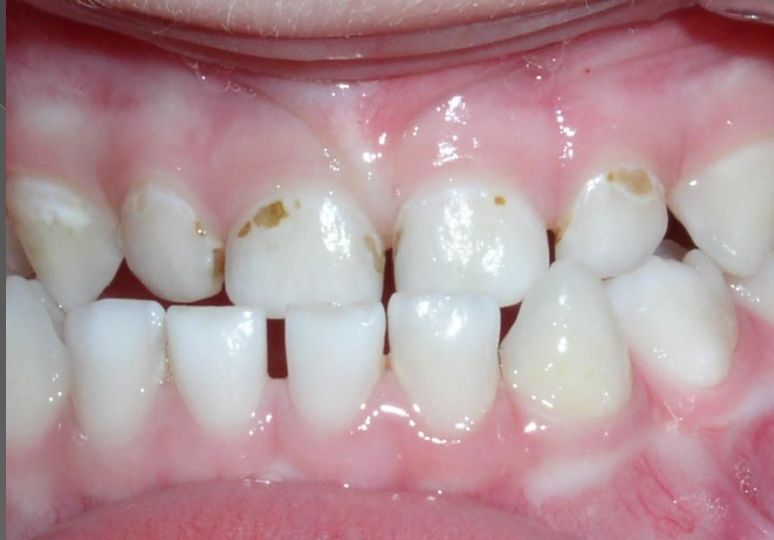Mouth treasure



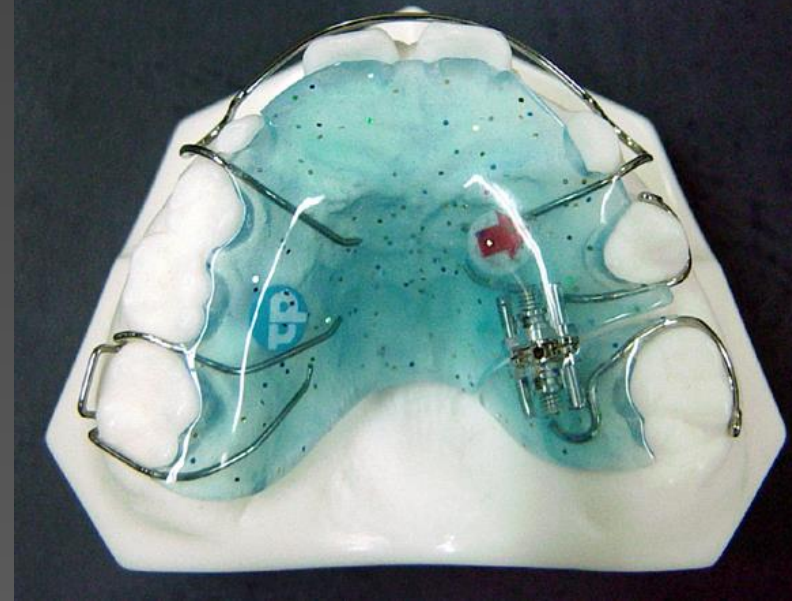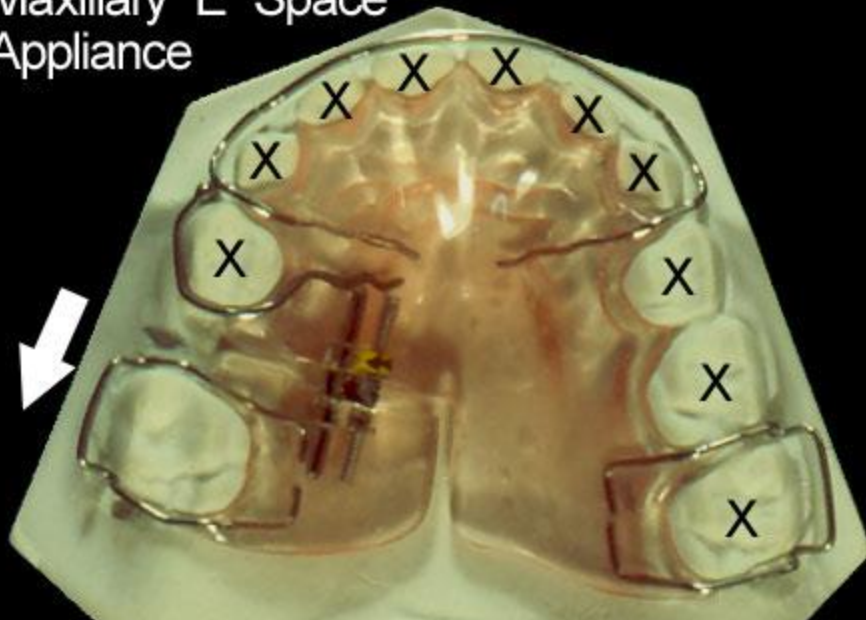
=







Maxillary "E" Space Appliance



Mandibular "E" Space Appliance

